



JİNEKOLOJİK ENDOSKOPİ PLATFORMU



6. MİNİMAL İNVAZİV JİNEKOLOJİK CERRAHİ KONGRESİ

21-24 Haziran 2023 | Acıbadem Üniversitesi Kongre Merkezi, Ataşehir - İSTANBUL

Vulva'da Minimal İnvaziv Kozmetik Jinekolojik Uygulamalar: Lazer ve İp Askı Uygulamaları

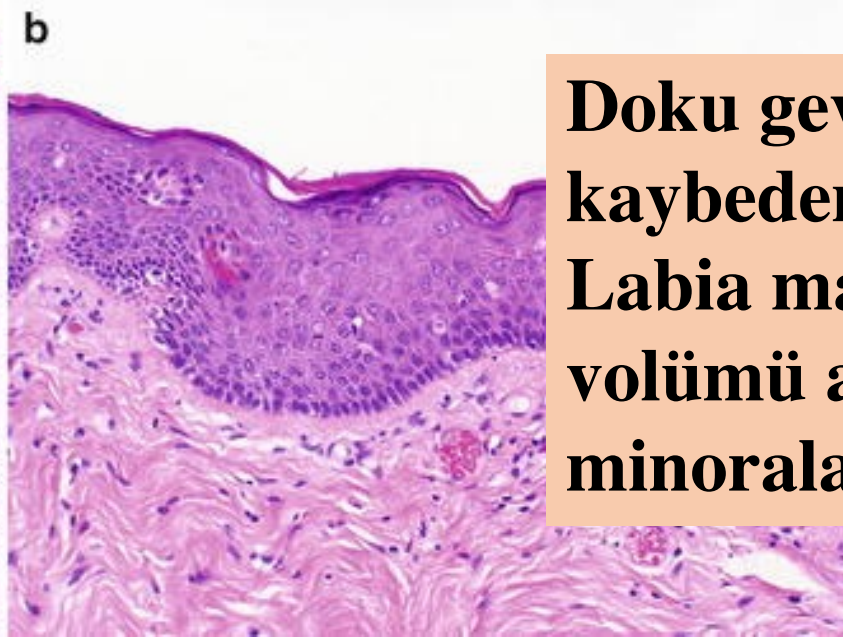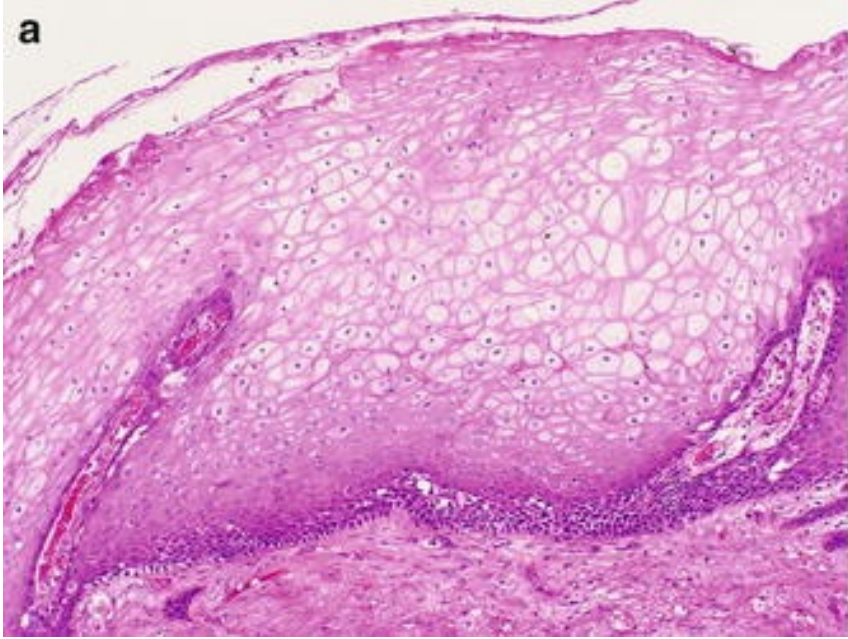
Ebru Alper

Amerikan Hastanesi, Kadın Sağlığı Ünitesi

Kadın eksternal genityasının yaşlanması

Vulvar epitel kalınlığı reproduktif dönemde en kalın haline ulaşırken, yaşla birlikte incelir.

Estrogen her menstrüel döngüde süperfisiyel epitelyal hücrelerde nükleer modifikasyonu indükler.



Doku gevşer, elastisitesini kaybeder.
Labia majoranın tonusu, volümü azalırken labia minoraların boyutları artar.

VULVAR REJUVENATION

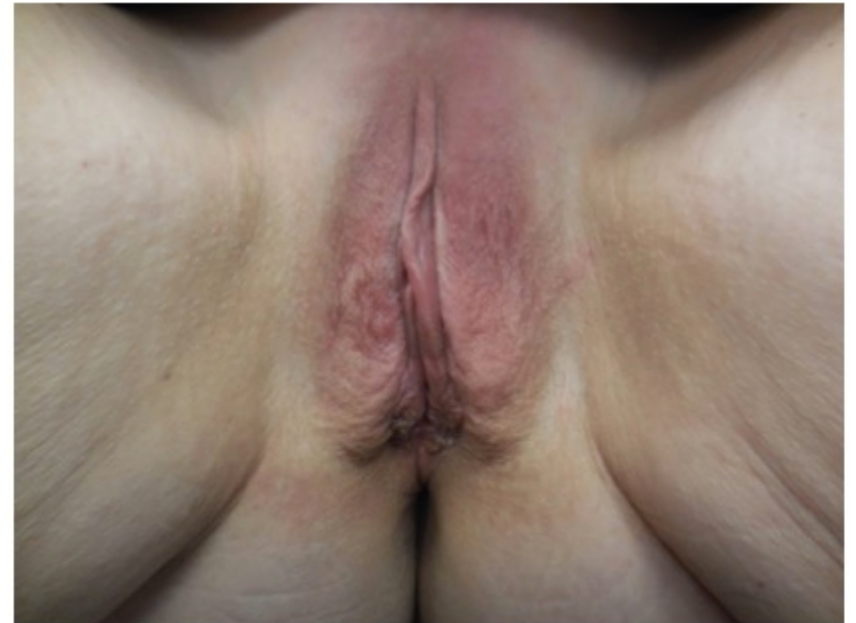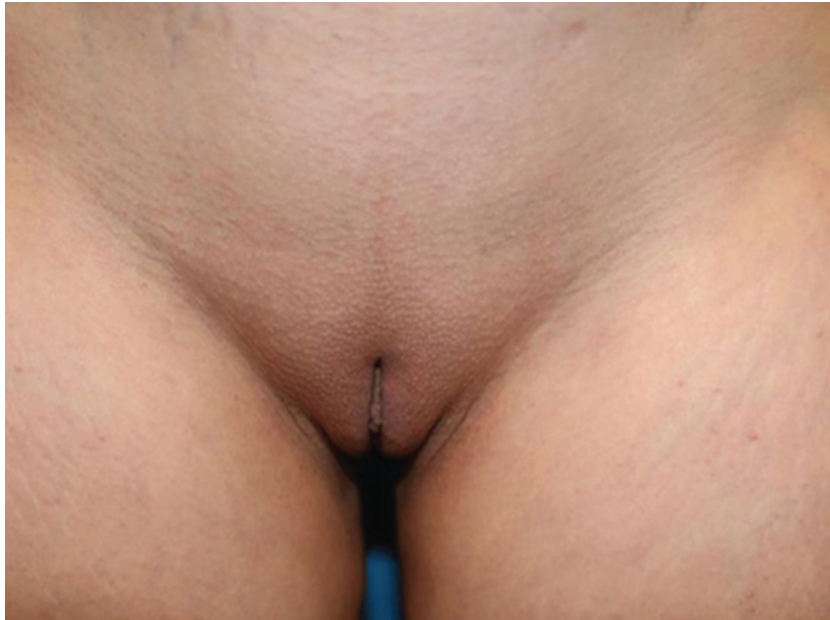Eksternal genitaliyayı estetik açıdan güçlendirmek

Daha genç bir görünüm elde etmek

Bu prosedürle dış genitaliyayı gençleştirmek, volüm ve nem kazandırmak ve böylelikle pozitif fizyolojik bir etki yapılması amaçlanır.

Table 1. Classification of Labia Majora Hypotrophy

	Subcutaneous Layers	Cutaneous Layer	Symptoms
Stage I - Mild (Early)	Mild hypotrophy. Distribution of adipose tissue is usually symmetrical.	None to mild cutaneous hypotrophy. Thin wrinkles may be visible.	Usually asymptomatic. Possible consequence of weight loss.
Stage II - Moderate	Moderate hypotrophy. Possible asymmetric distribution of adipose tissue.	Moderate cutaneous laxity, dermatochalasis. Wrinkles are visible.	Dryness, dyspareunia, soreness could be observed.
Stage III - Severe	Severe hypotrophy. Frequent asymmetric distribution of adipose tissue.	Severe dermatochalasis and deep wrinkles.	Usually associated to symptoms like dryness, dyspareunia, soreness.



Nemlendirme



Vulvar Lazer

Tightening

Bleaching

Hacim kazandırma



Vulva İp Askı

Yeniden yapılandırma

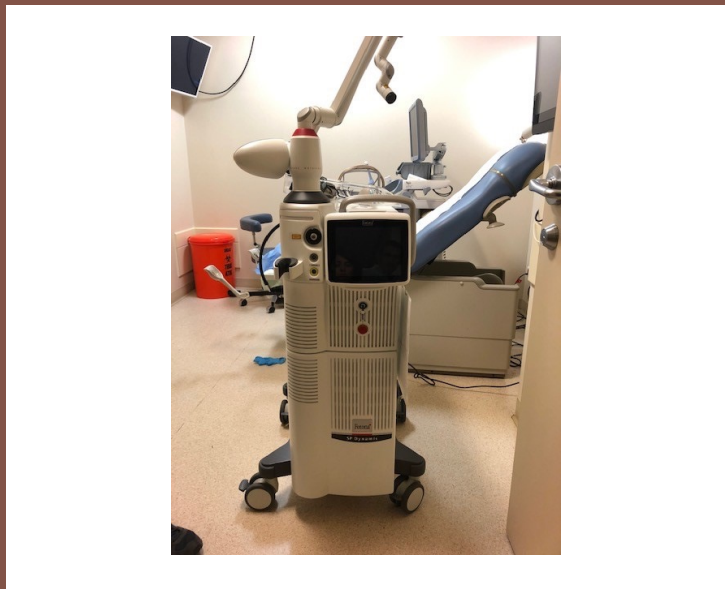
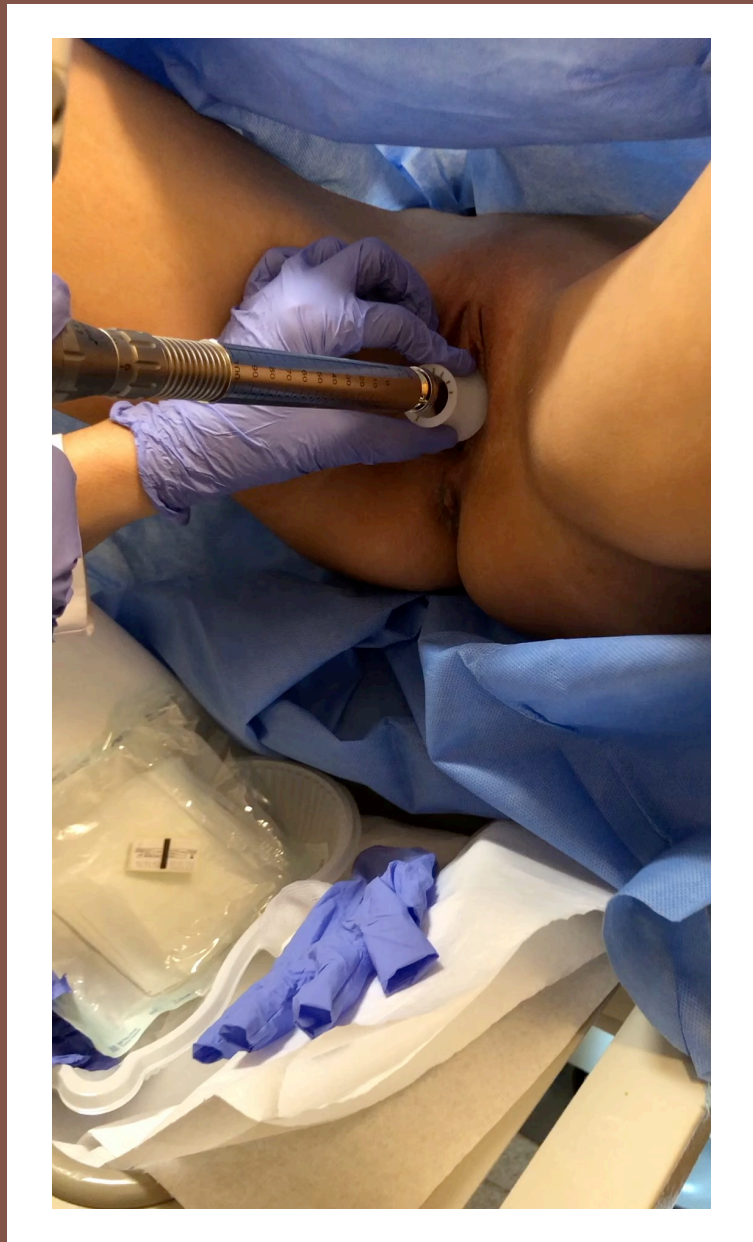
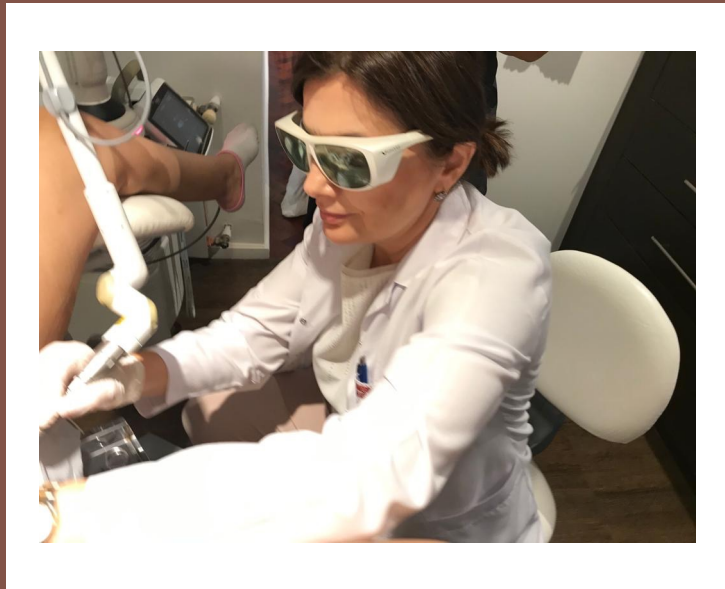


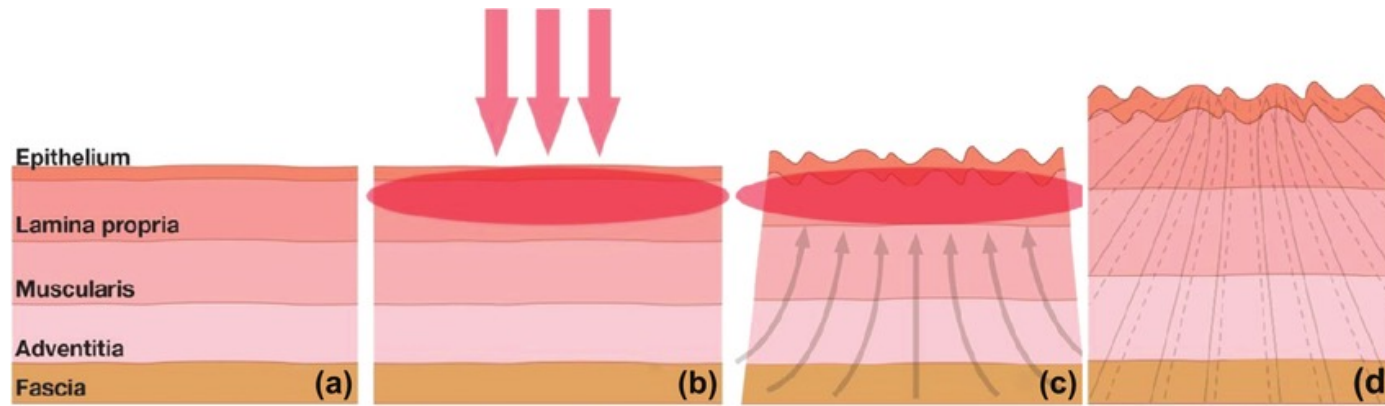
Vulvar Laser Tightening

This is the protocol used to improve the overall quality of the skin in the female genitalia.

It involves the tightening of the labia majora.

Most patients seeking this treatment are cases in which the area's fat deposit is lost due to weight loss.





- Increase of collagen
- Increase of acidic mucopolysaccharides in the ground matrix
- Increase of glycogen content and delivery

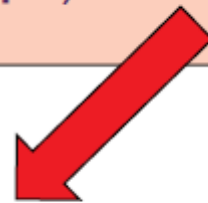


better mechanical support

better mucosal hydration and permeability to nutrients and hormones

increase of lactobacilli activity (< pH)

- collagen formation in the lamina propria,
- improves natural lubrication and control of urination



Vulva

VAGINAL HEALTH RESTORATION

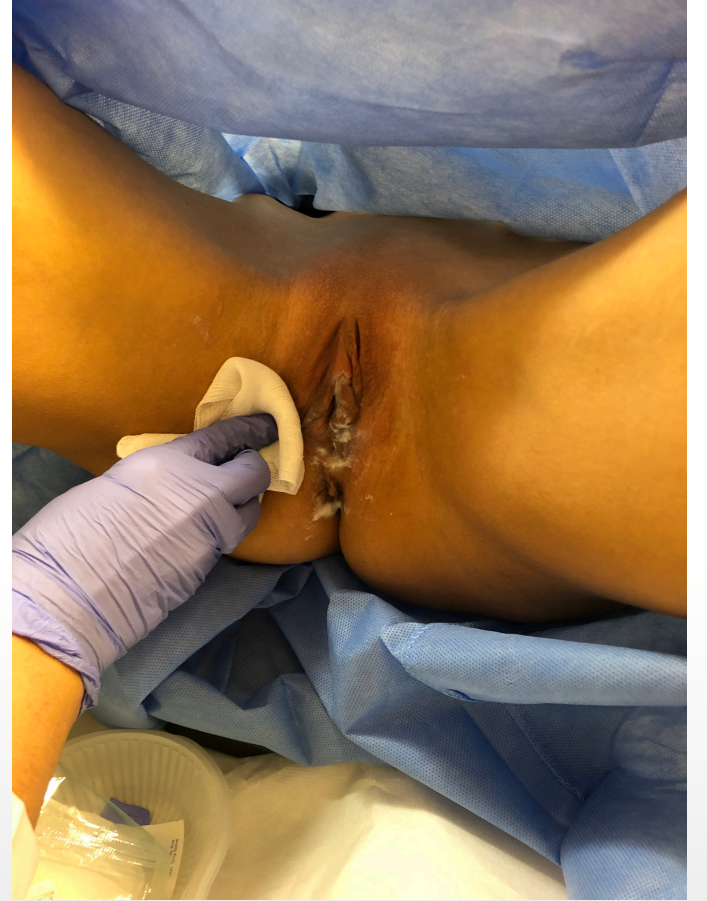
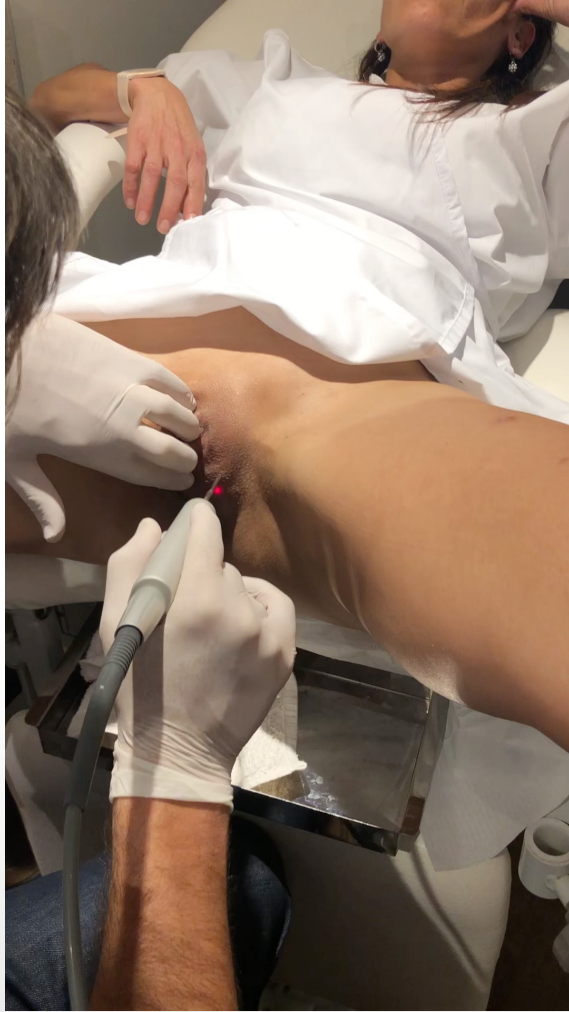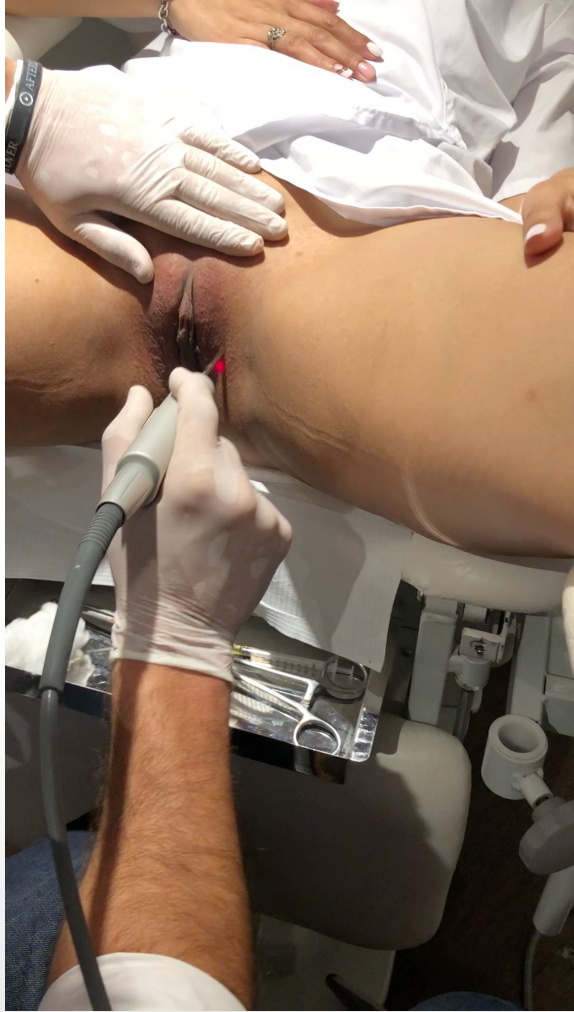- Kollajen pelvik tabanın destek yapıları arasında en önemli protein yapıdır.
- Endopelvik fasyanın protein içeriğinin %80'inden fazlasında kollajen bulunmaktadır.

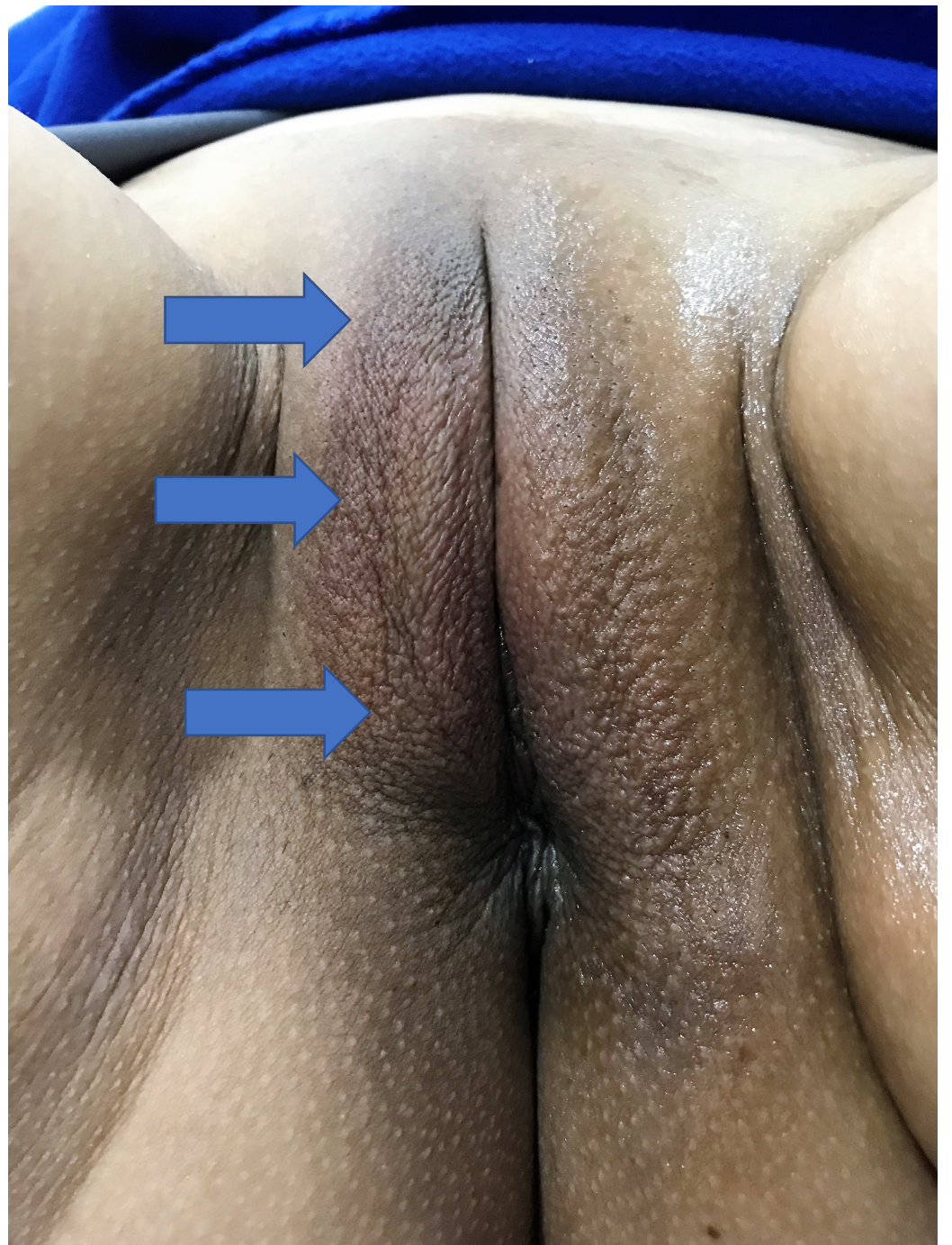
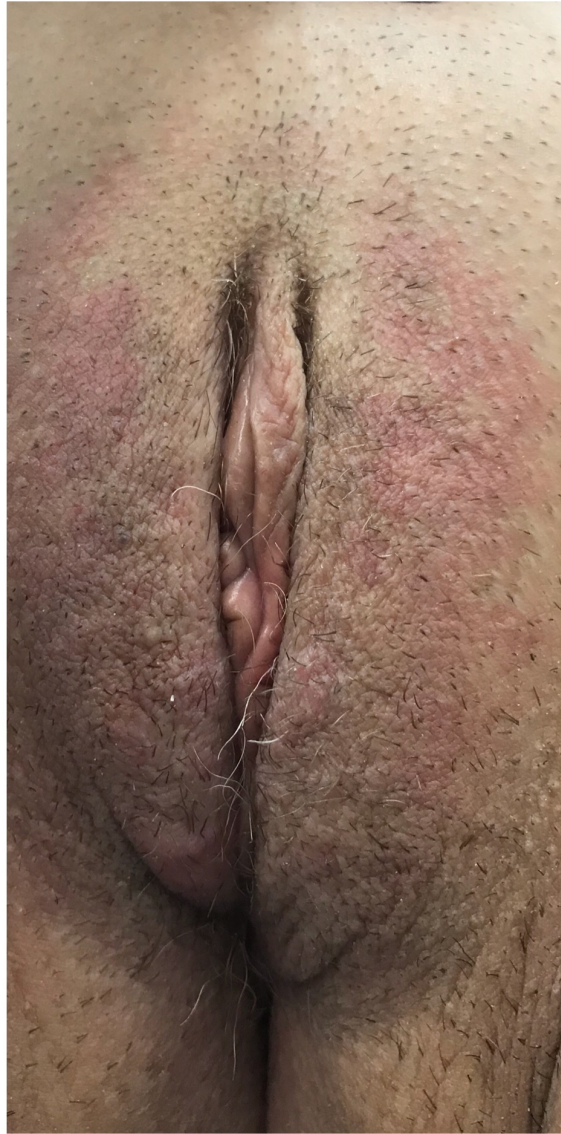Doğum

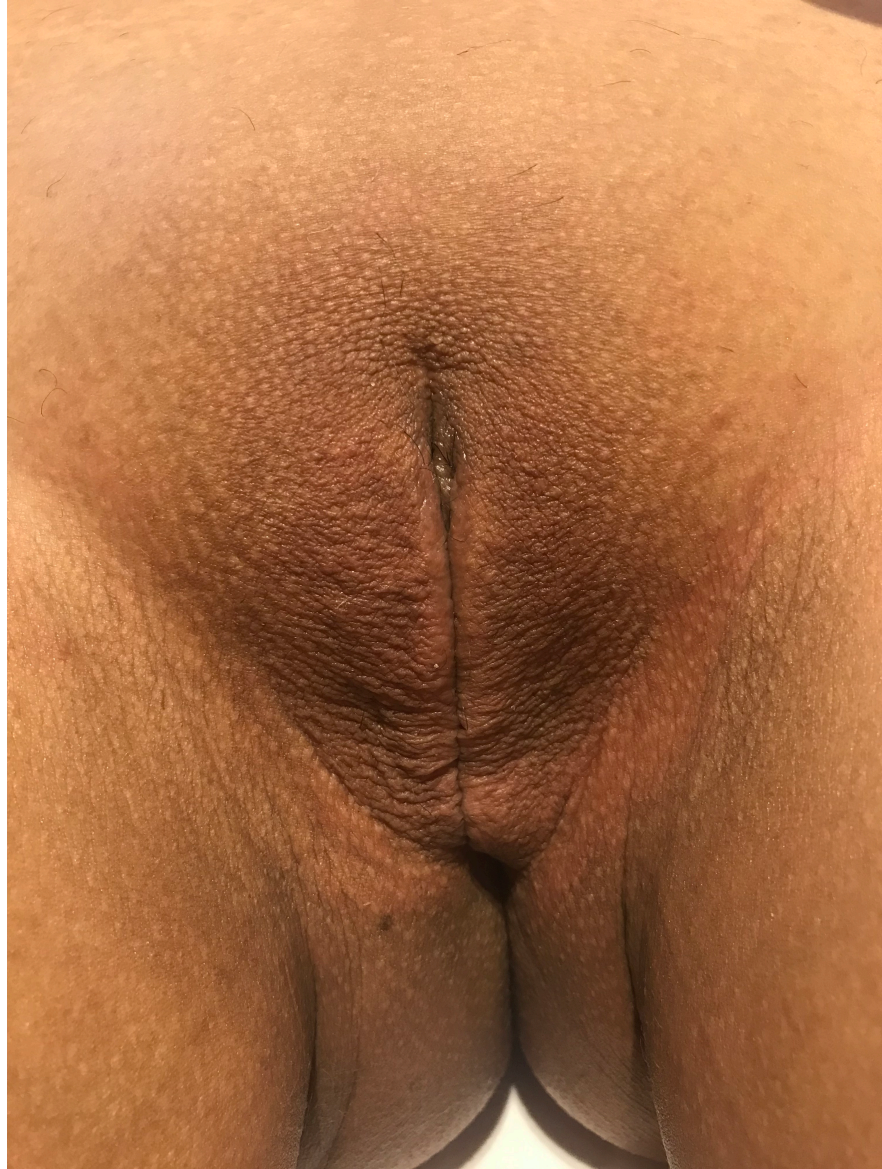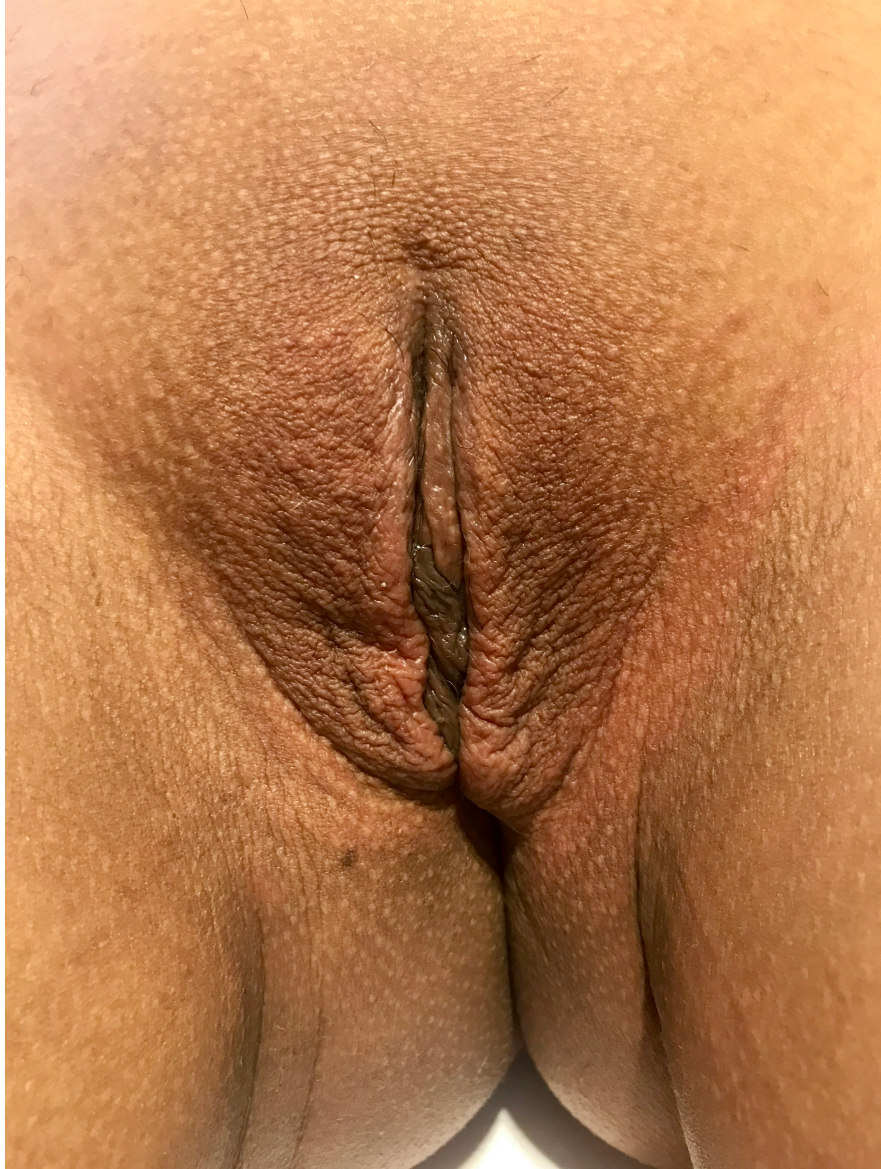Pelvik tabanda kollajen liflerinin yıkılmasına neden olur

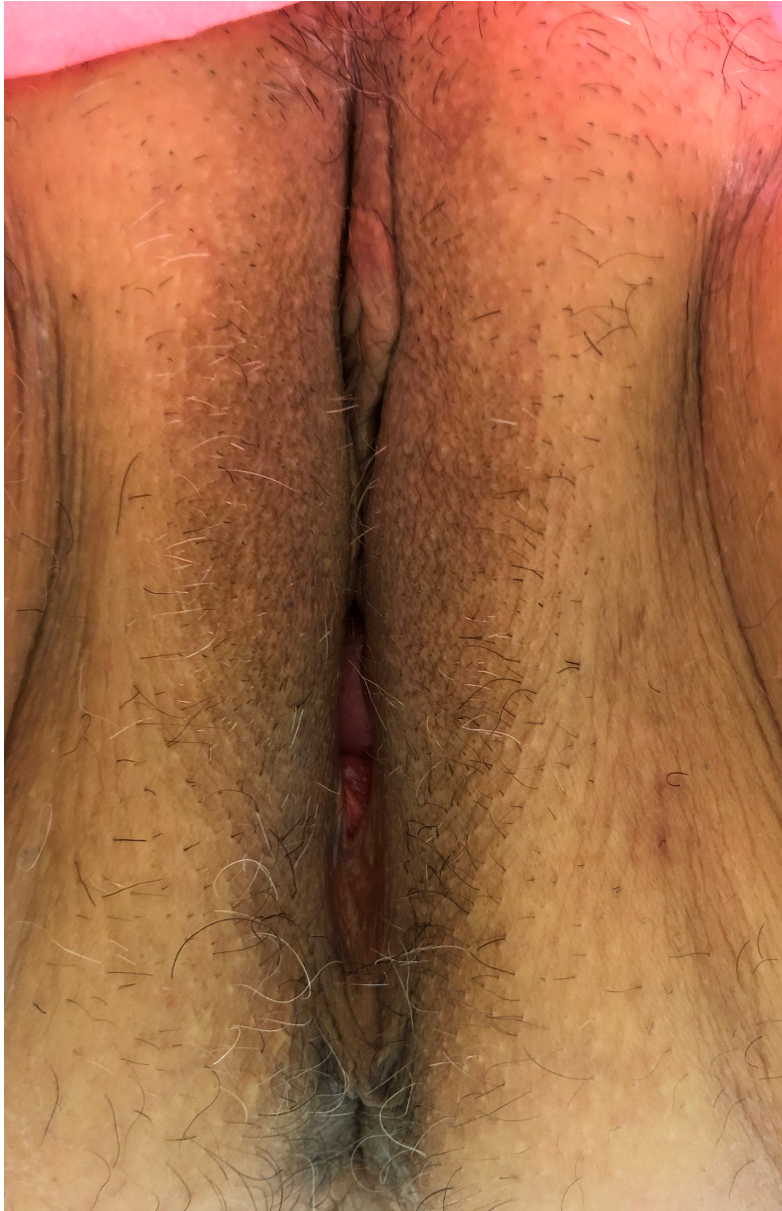Yaşlanma

Yeni kollajen sentezinde azalmaya neden olur










VULVAR BLEACHING



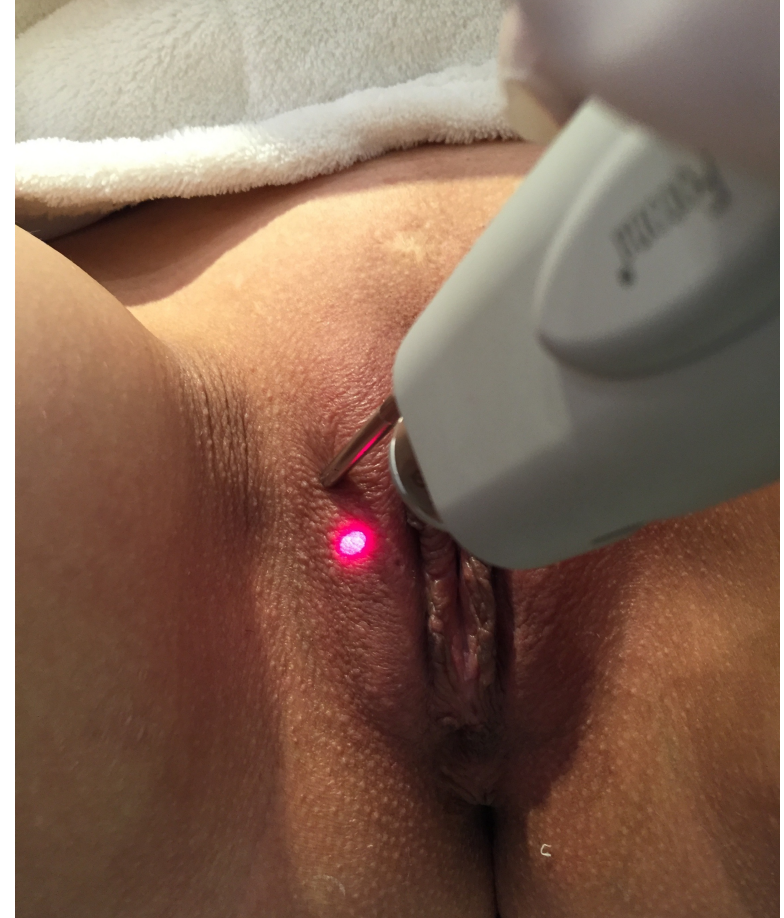
Genital hyperpigmentation is darkening of the skin around the external genitalia and anal area.

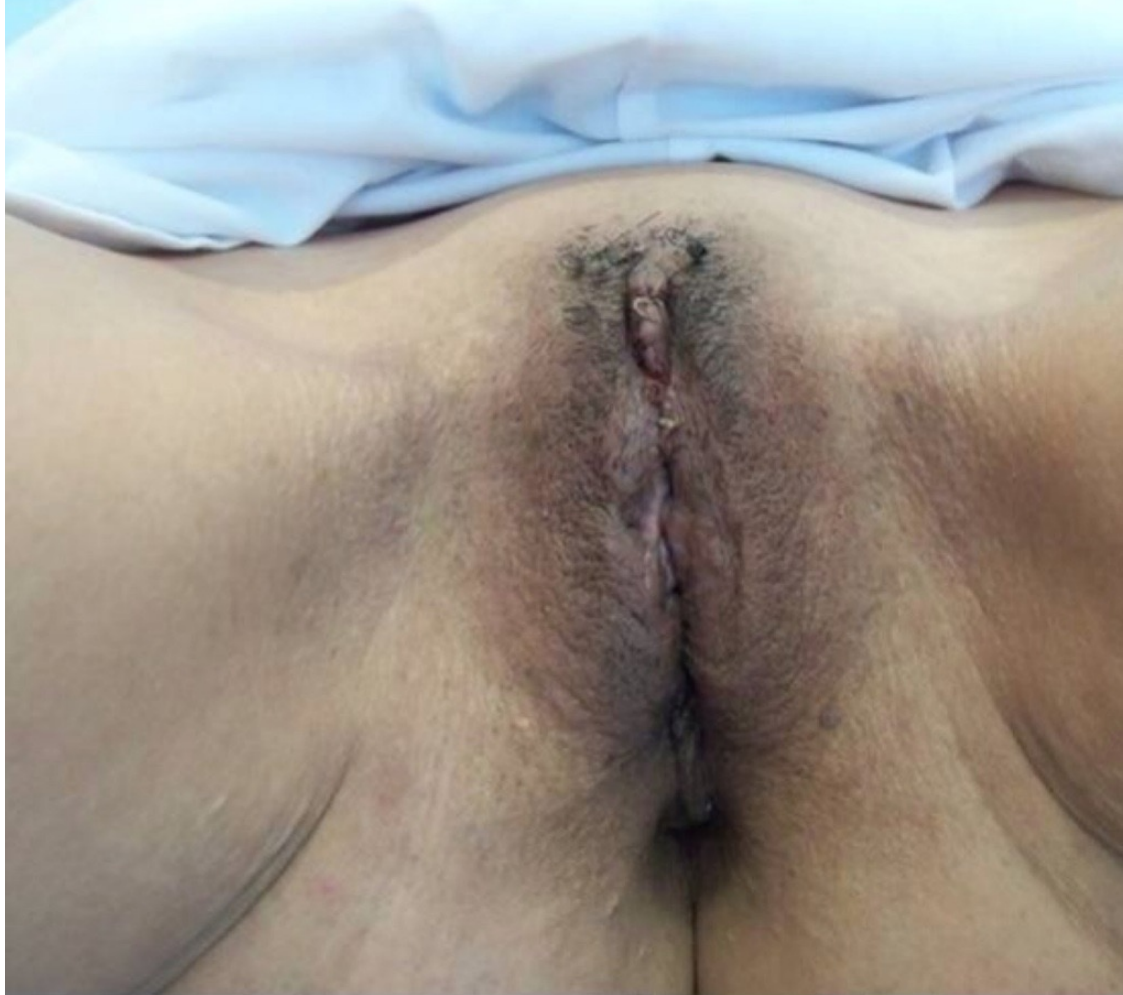These are symmetrical lesions, without changes in the texture of the skin

The cause is unknown, but there is genetic and racial predisposition.

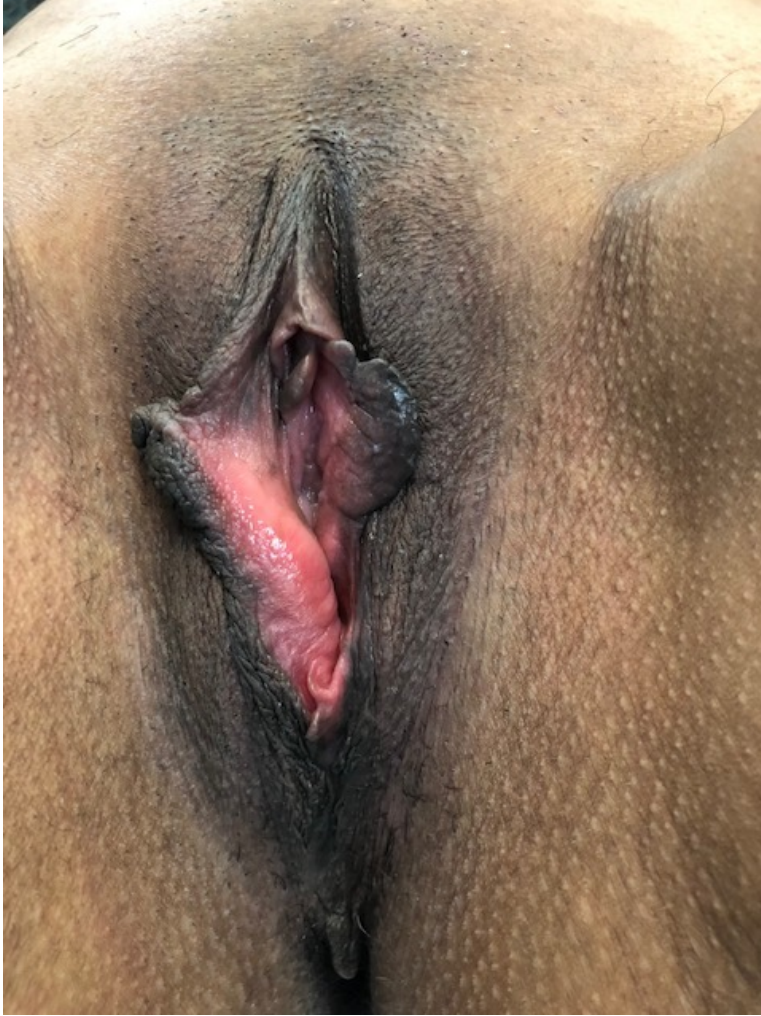Hormonal problems/ hyperinsulinism/ CAH/ Addison's disease/
Cushing's disease/ Pregnancy

ERBIUM:YAG BLEACHING

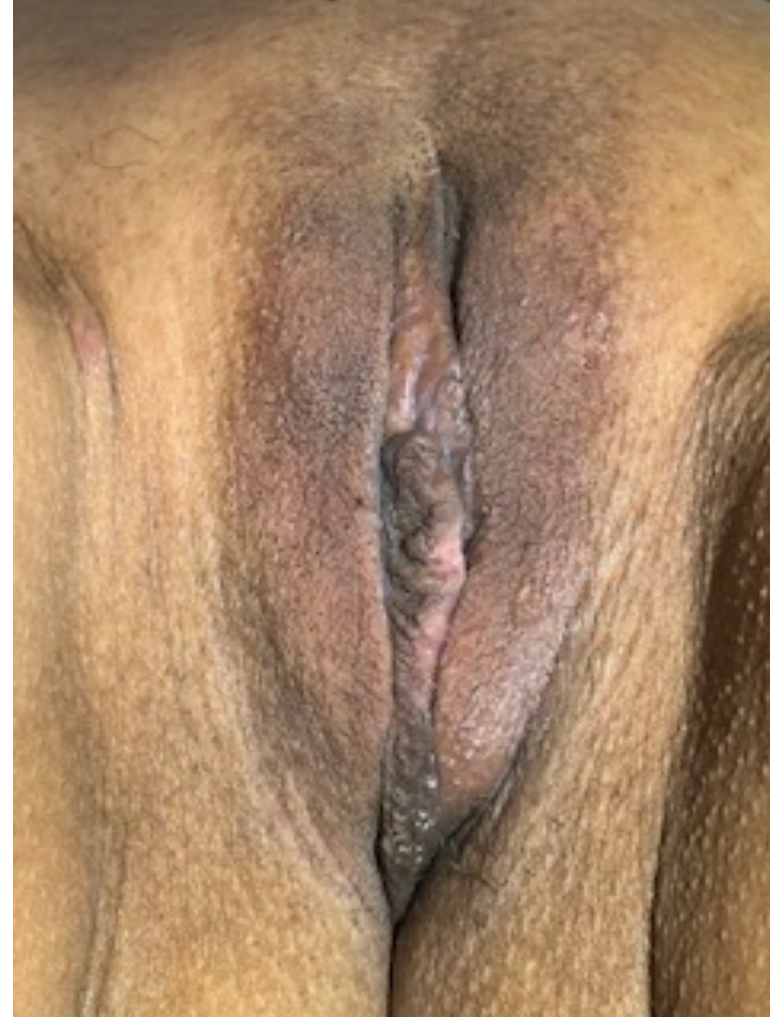



Labioplasti ve laserle
hiperpigmentasyon tedavisi



Post op 6. ay ve 2 seans laser
sonrası



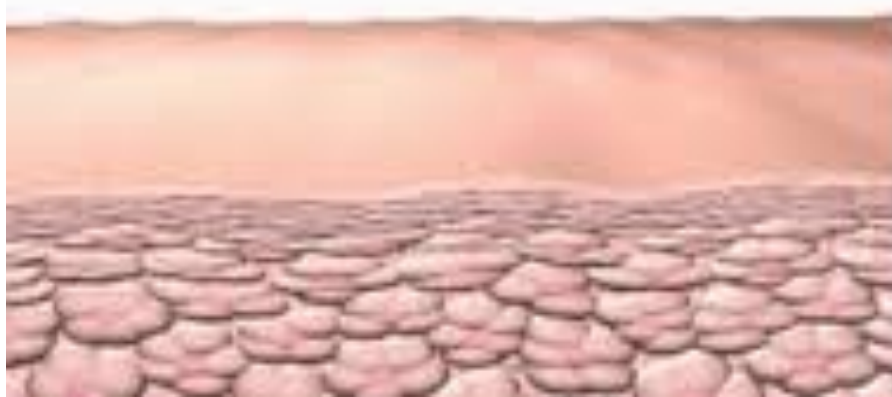
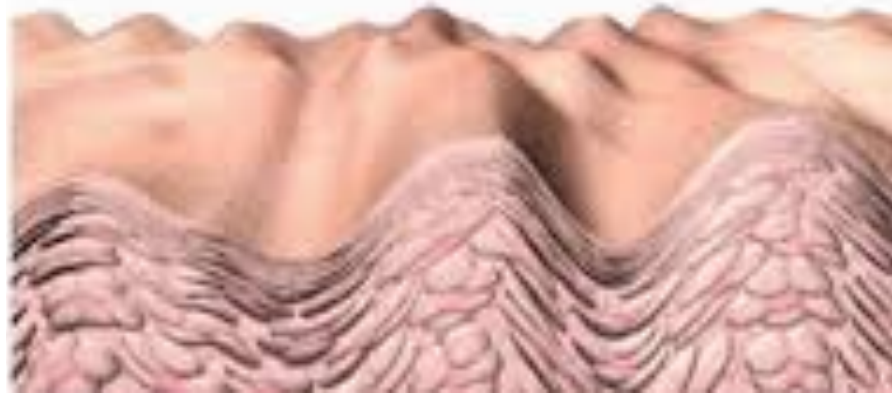Cosmetic Vulvar Lifting

İp askı / Threads (PDO & Prolene)

- Dokuya destek sağlayacak iskeleti oluşturmak
- Dokuda yaratılan lifting etkisi ile sarkık cildi farklı yönlere çeken vektörler yoluyla gerginleştirmek.
- Absorbable/ Non absorbable

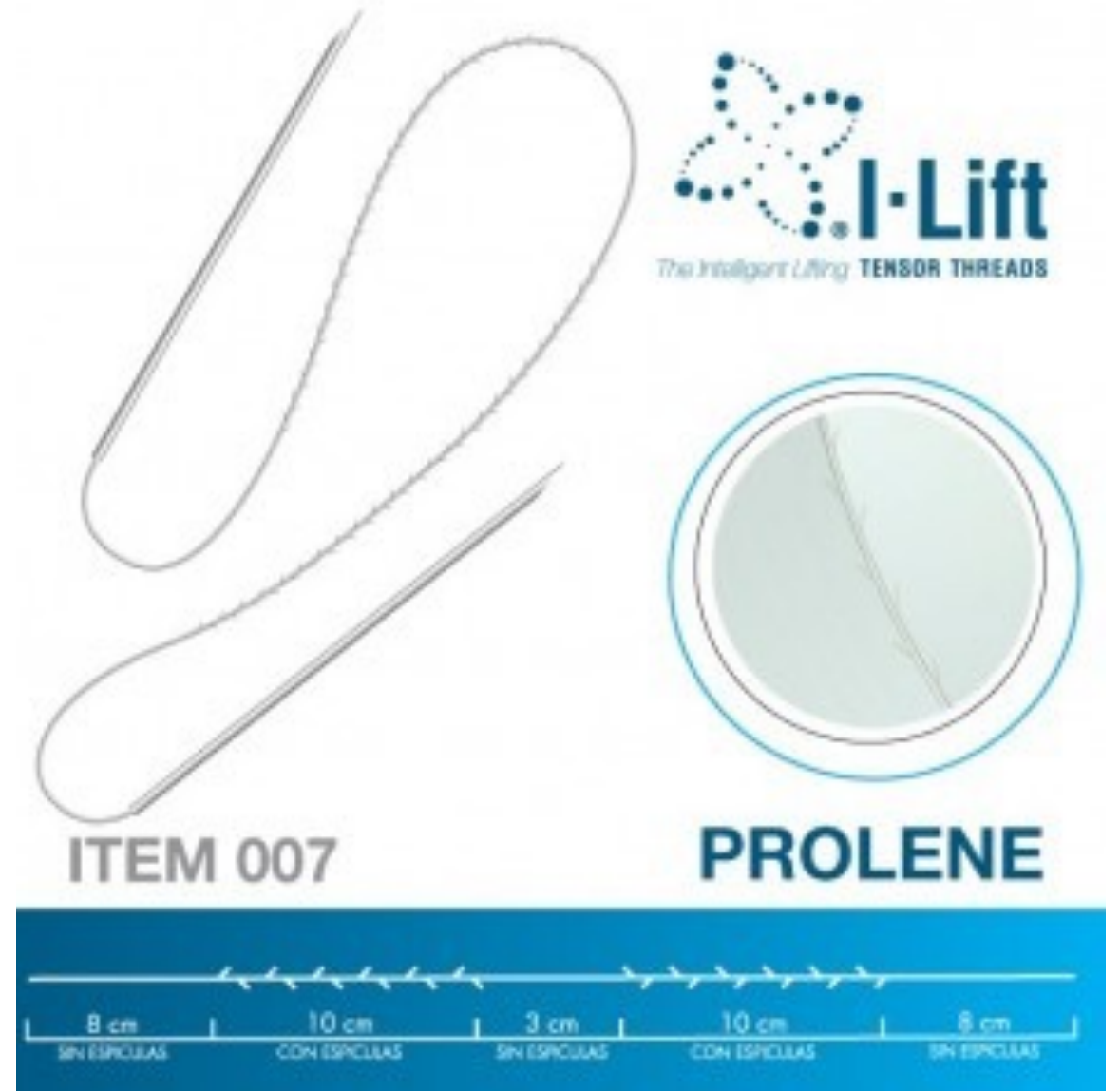PDO threads: 4 fonksiyonu var

- Lifting
- Sıkılaştırma
- Volum kazandırma
- Kollagenesis / Angiogenesis



Threads

- Non/ absorbable
- Farklı yönlerde doğru yönlendirilmiş spiküle çıkıntıları var
- Bu spiküle yapılar dokuyu farklı vektörel yönlerde doğru çekerek ciltte gerginlik sağlar
- Ciltte yeni kollojen oluşumunu sağlar



Etki mekanizması:

- İlk izlenen mekanik etkidir.
- Sürekli bir traksiyon sağlayarak etkisini gösterir.
- Yüzeydeki spiküllerin multipl fiksasyon noktaları oluşturarak yaptığı bu traksiyon tek noktaya çok fazla kuvvet gelmesini önlerken traksiyonun uygulandığı yüzeyi de arttırır.



Geç etki: Rejeneratif etki

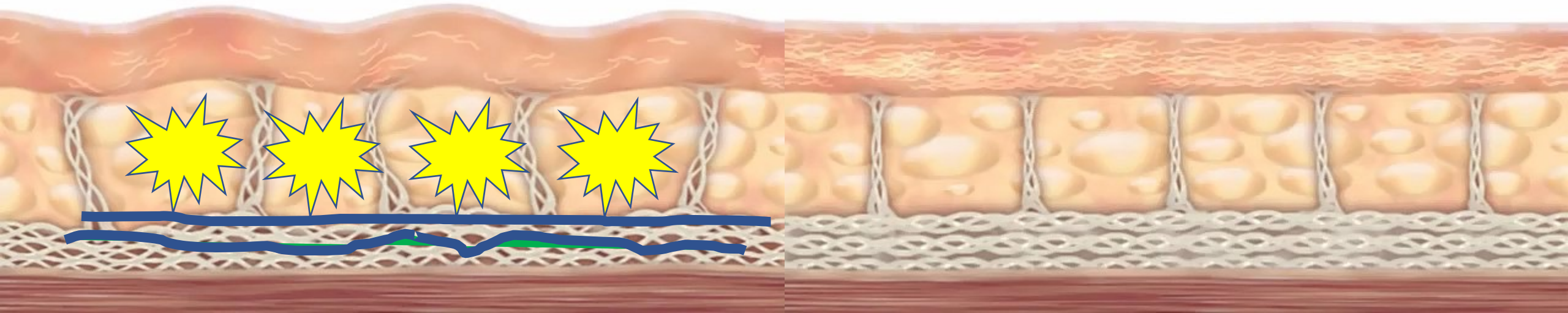
Mikrotravmanın yol açtığı inflamasyon, neovaskülarizasyon ve neokollojenez.
Tedavinin majör etkileri de işte bu mekanizmayla ortaya çıkar.

Komplet restoratif etki

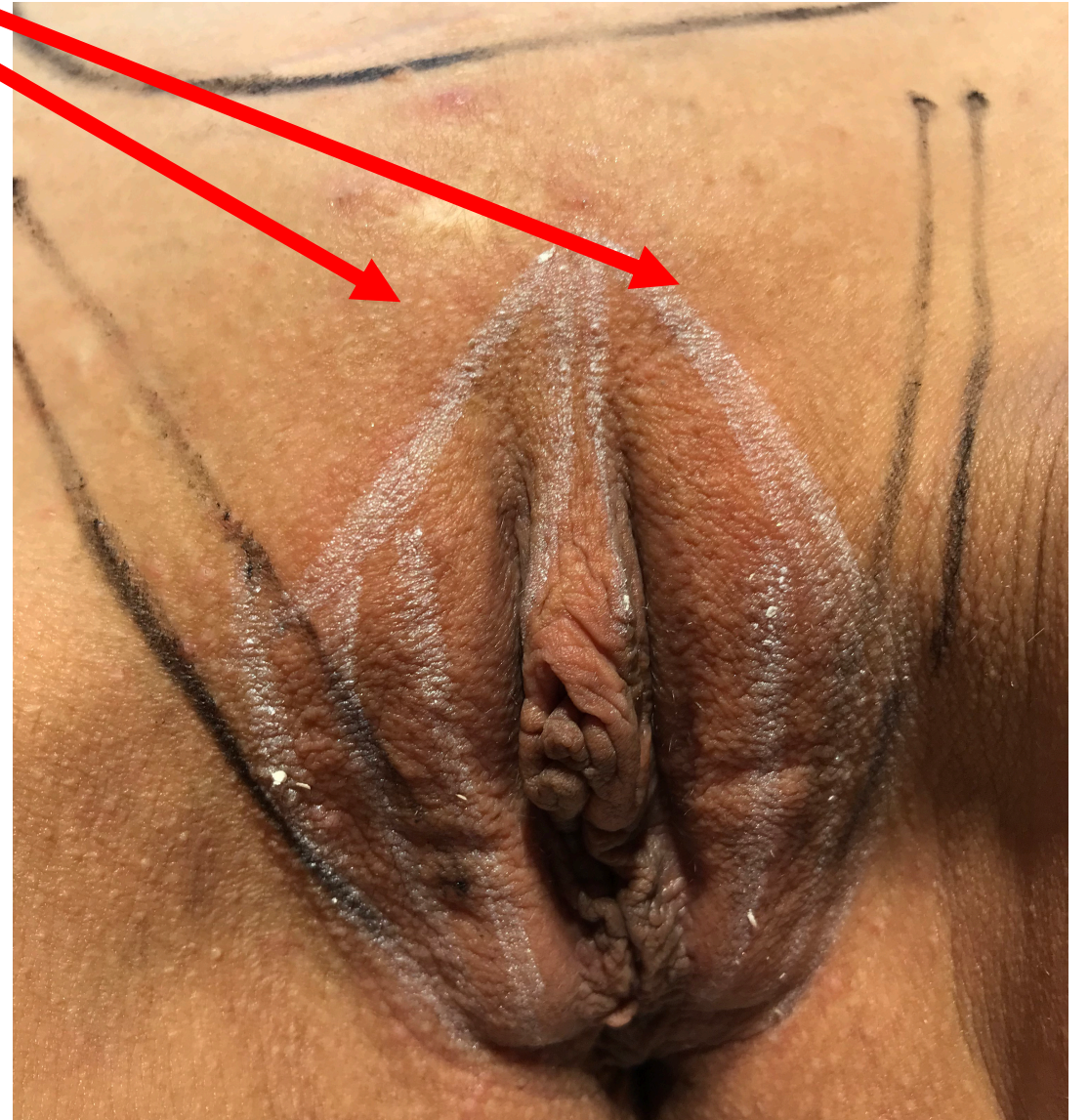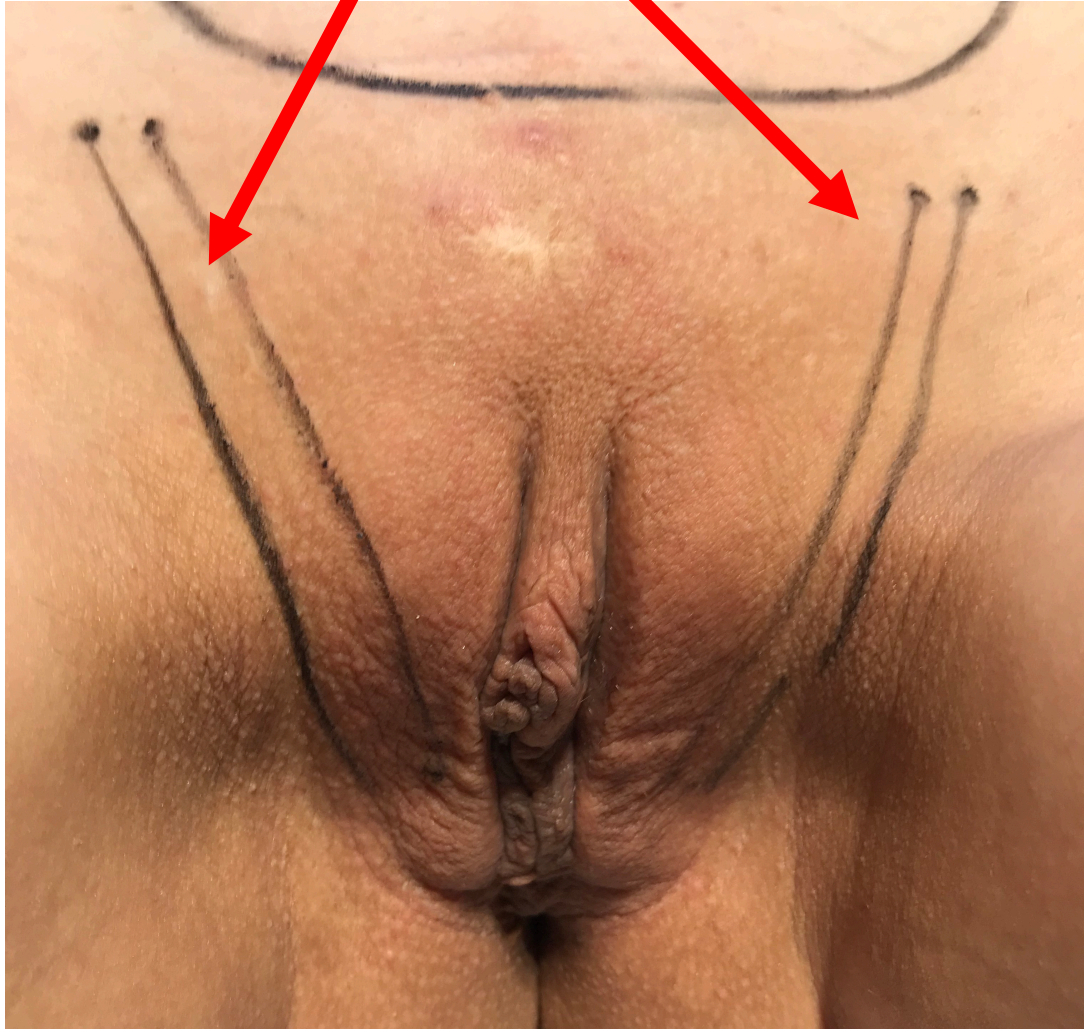
Neovaskülarizasyon

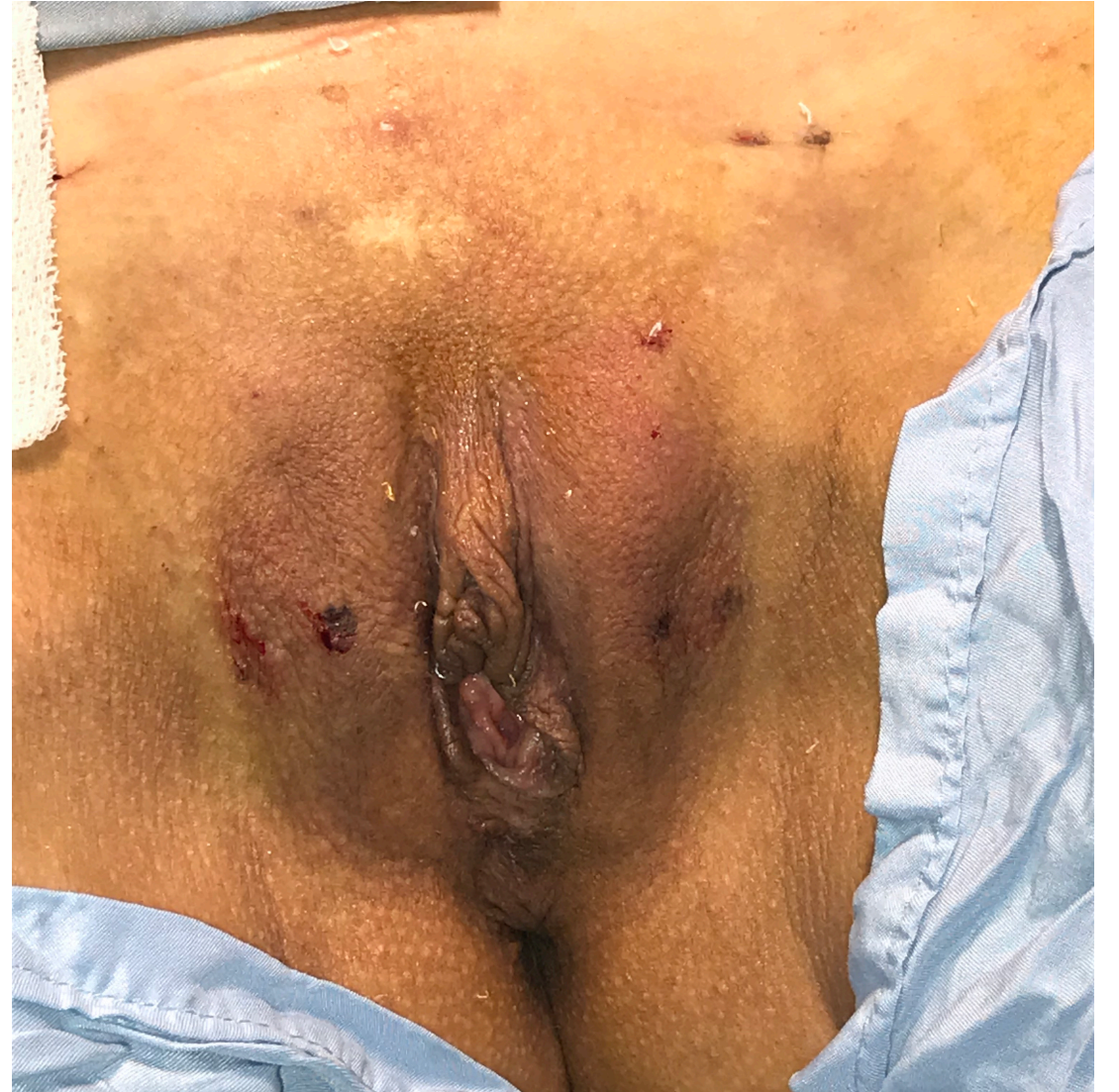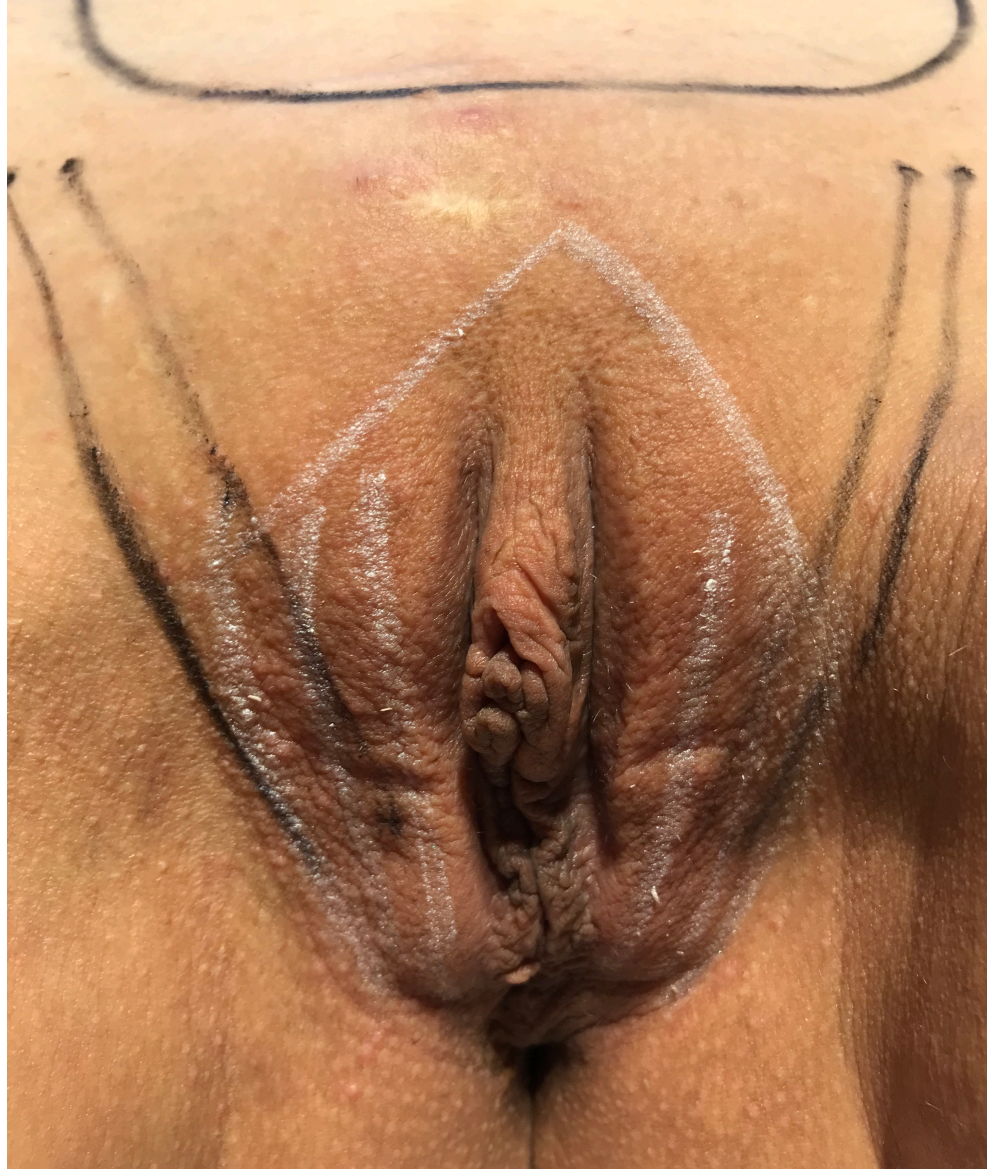Neokollajenez

Ciltte gerginlik, sıkılık ve elastisitede artış.

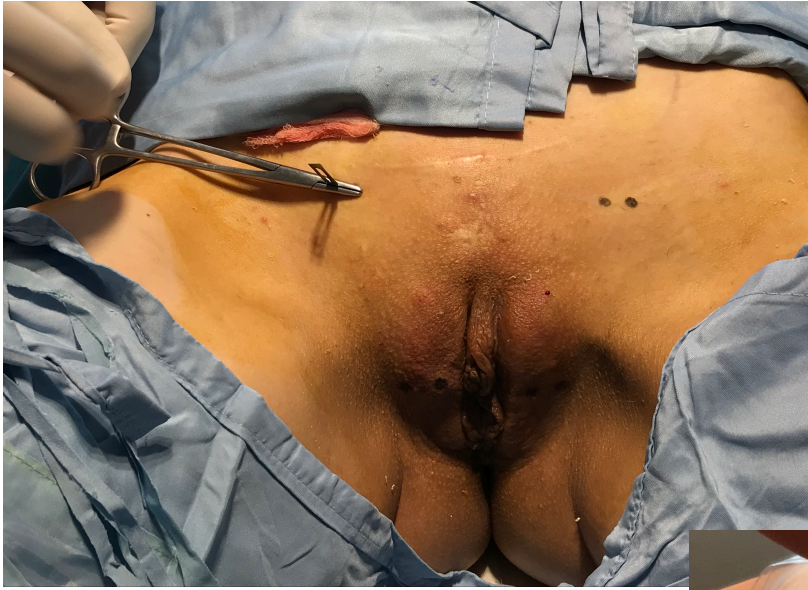

Threads: Prolene + PDO

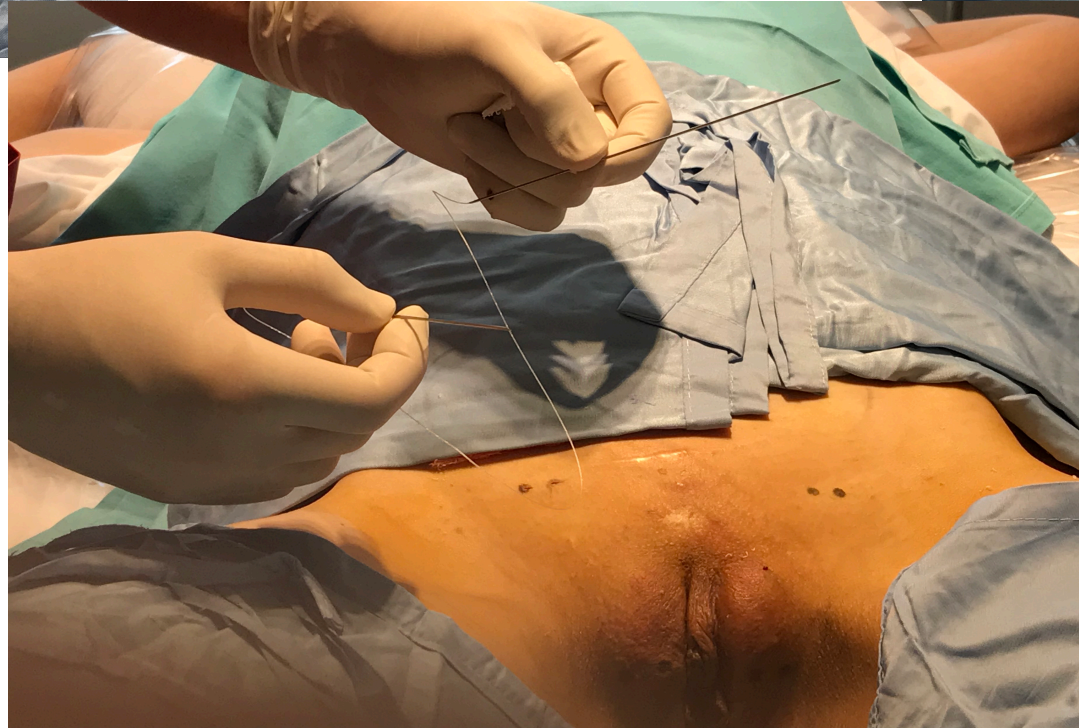
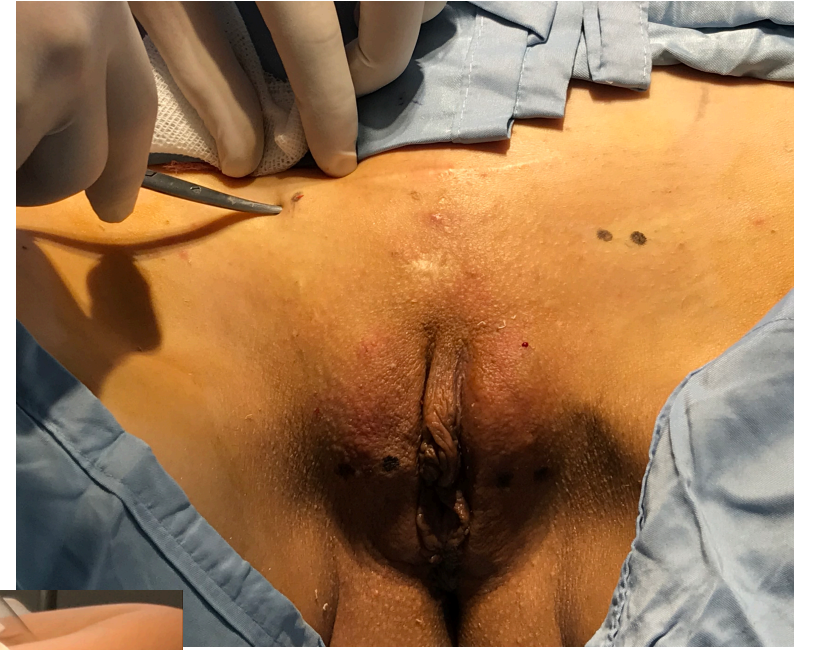


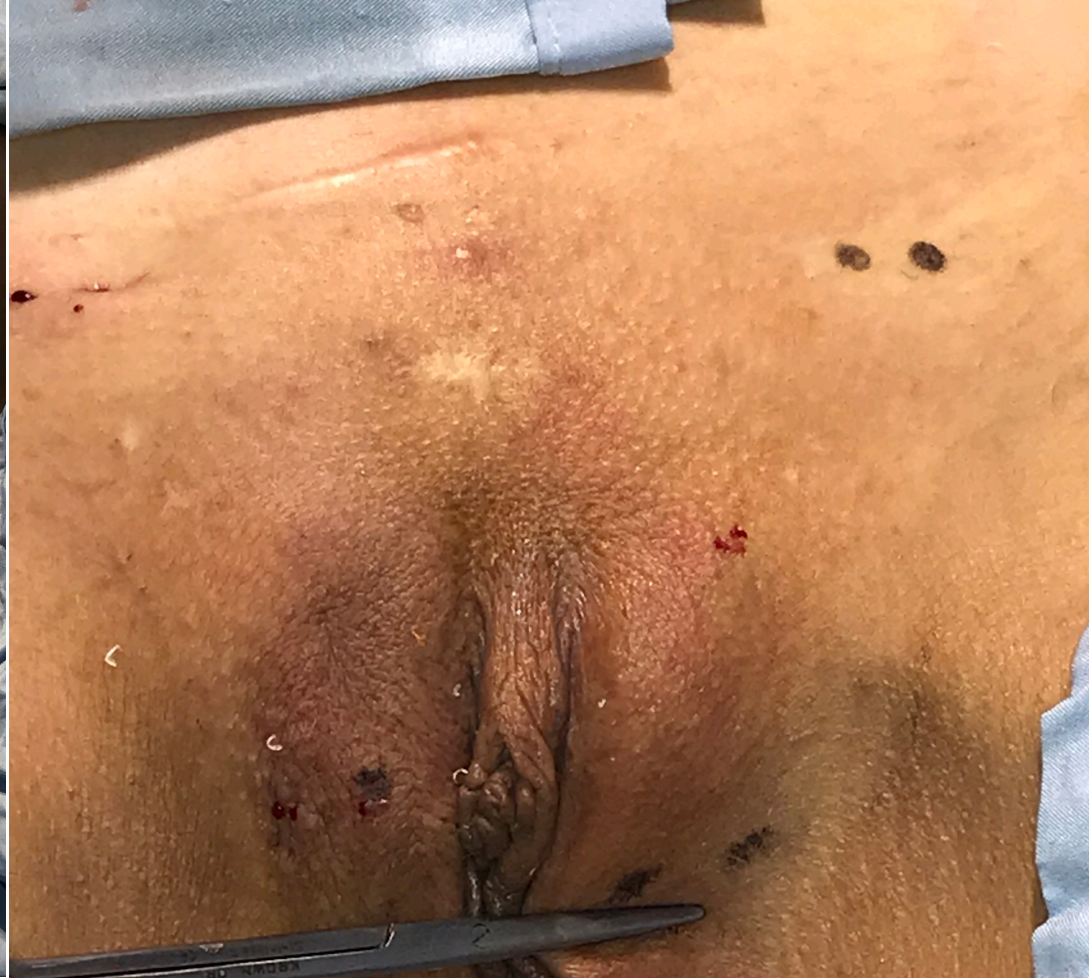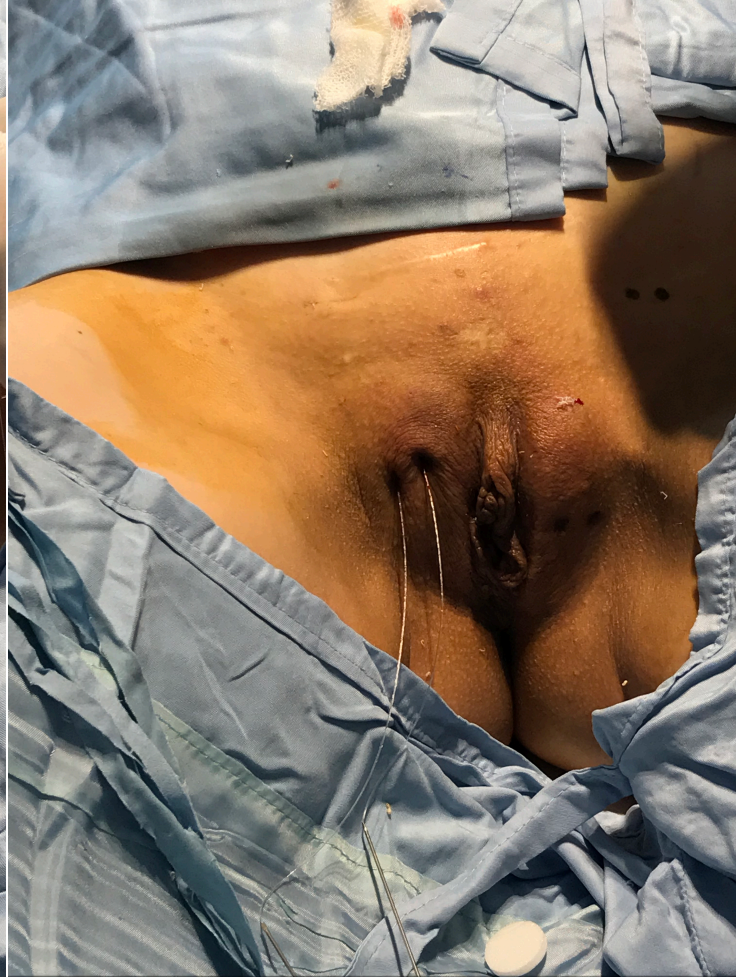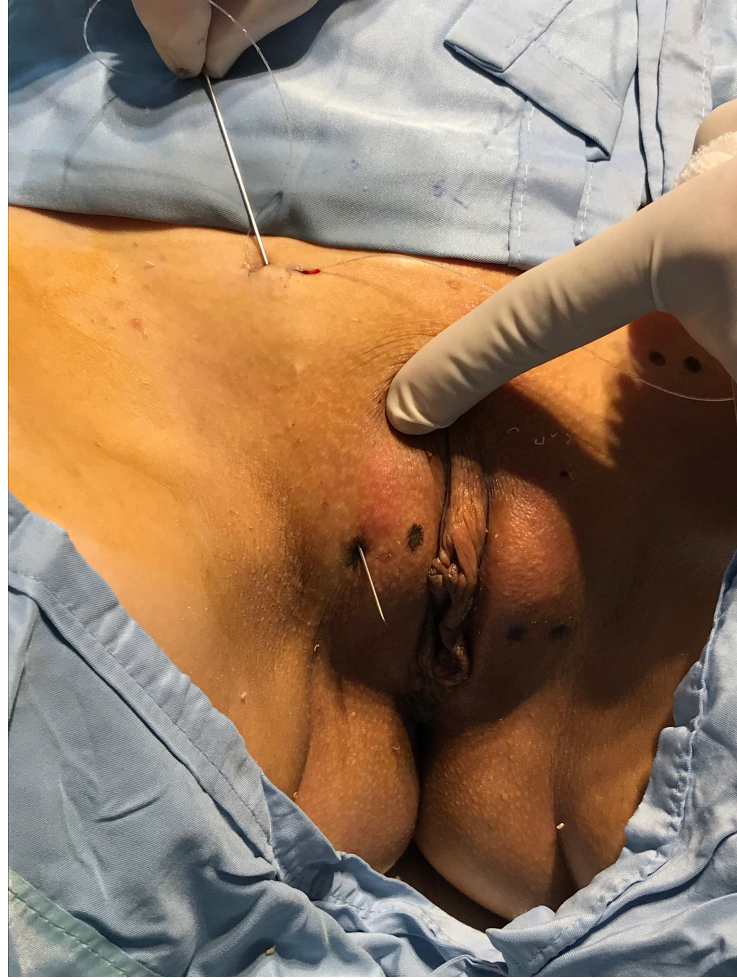İnsizyon



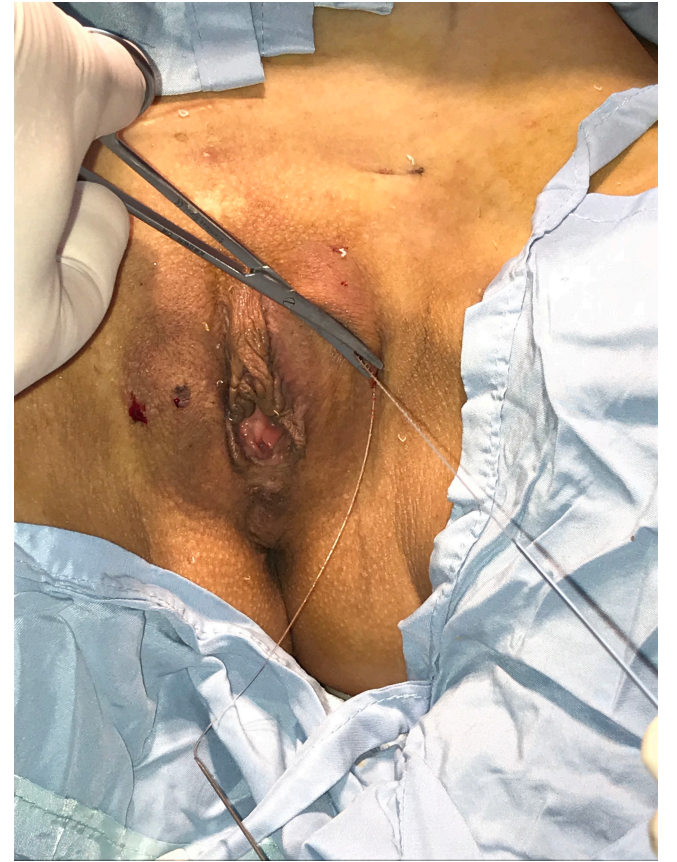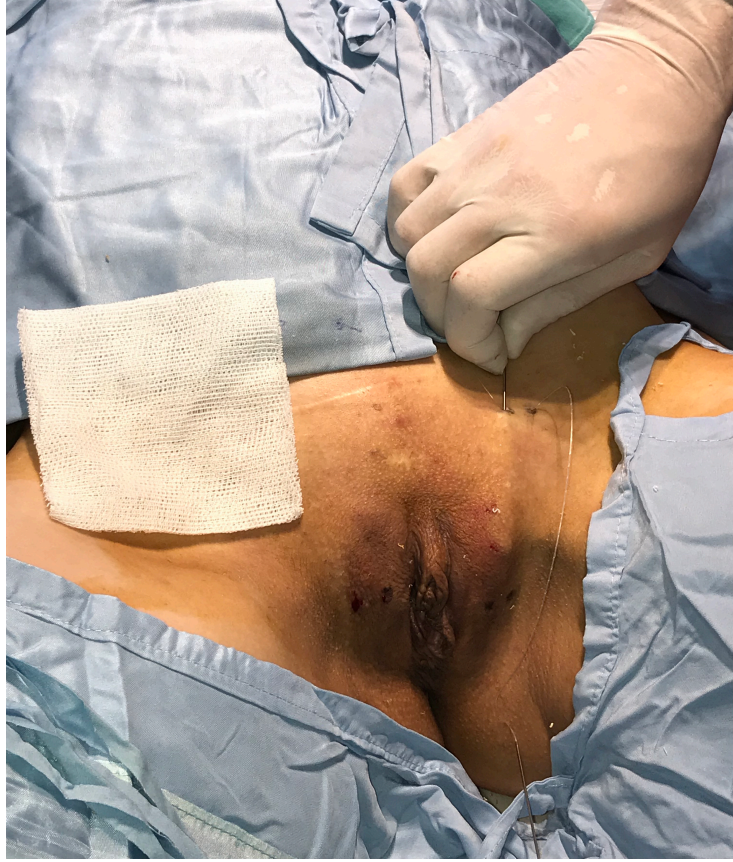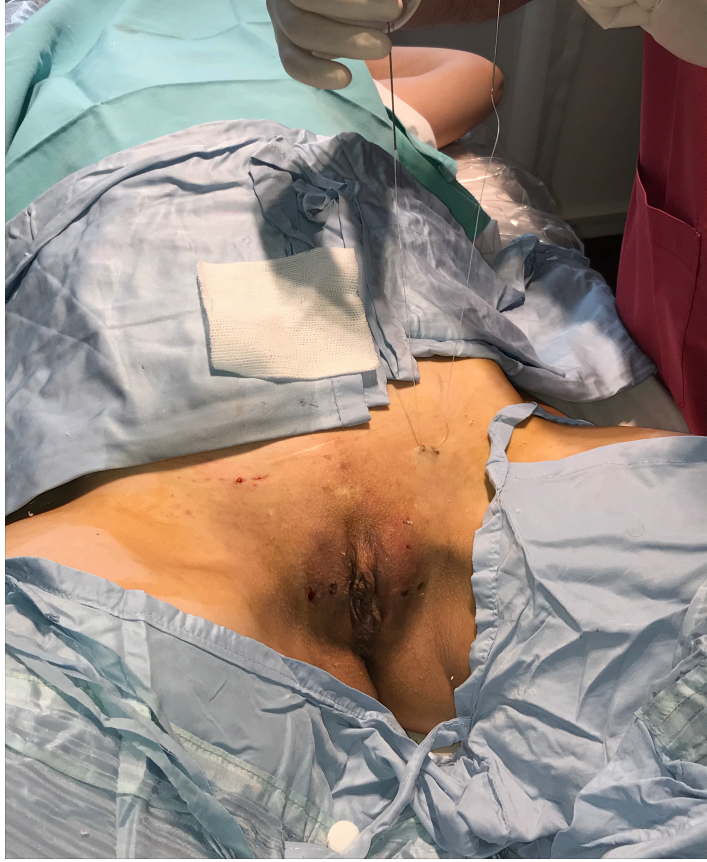Diseksiyon





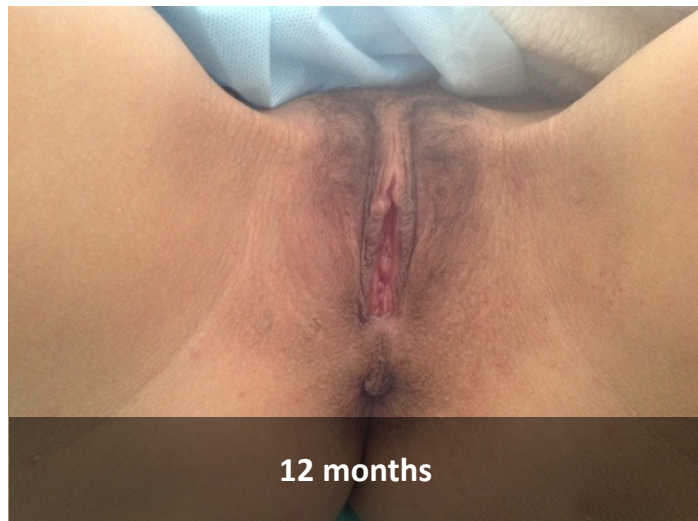
Her iki sûtür de yerleřtirildikten sonra cilde traksiyon oluřturulur.







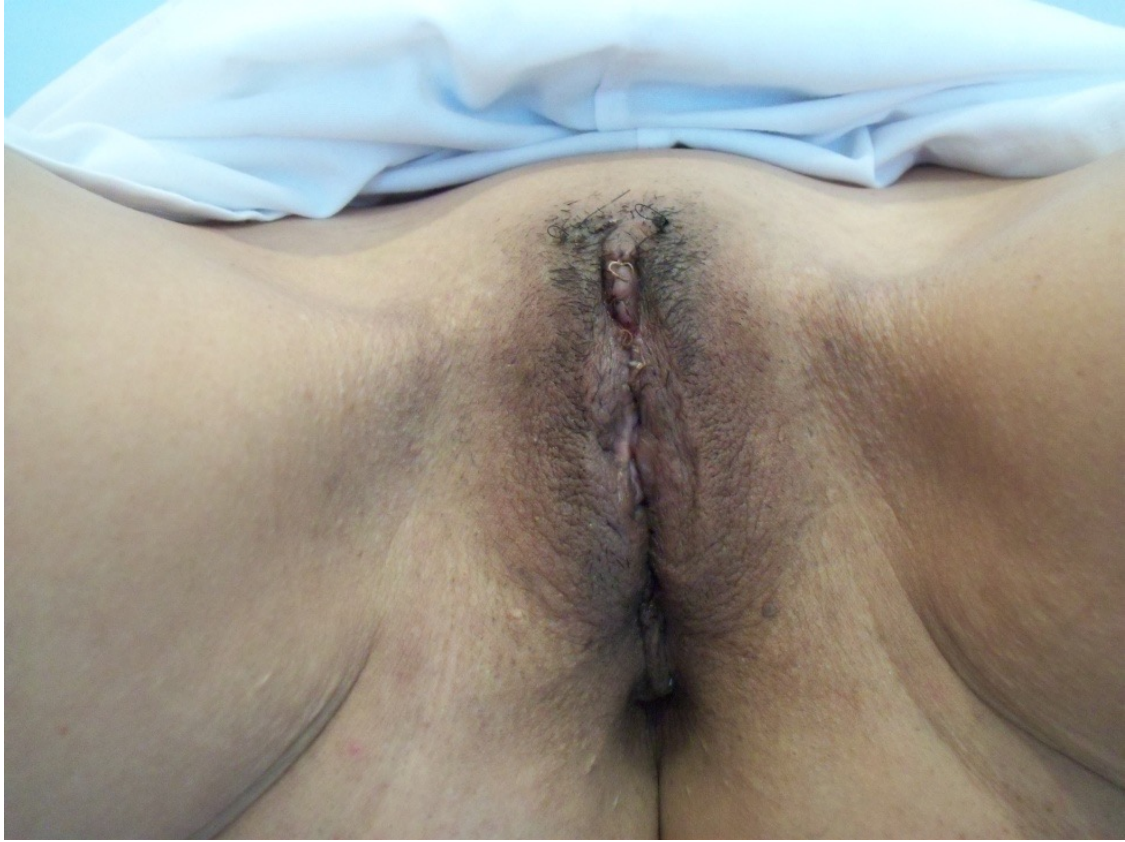3 months

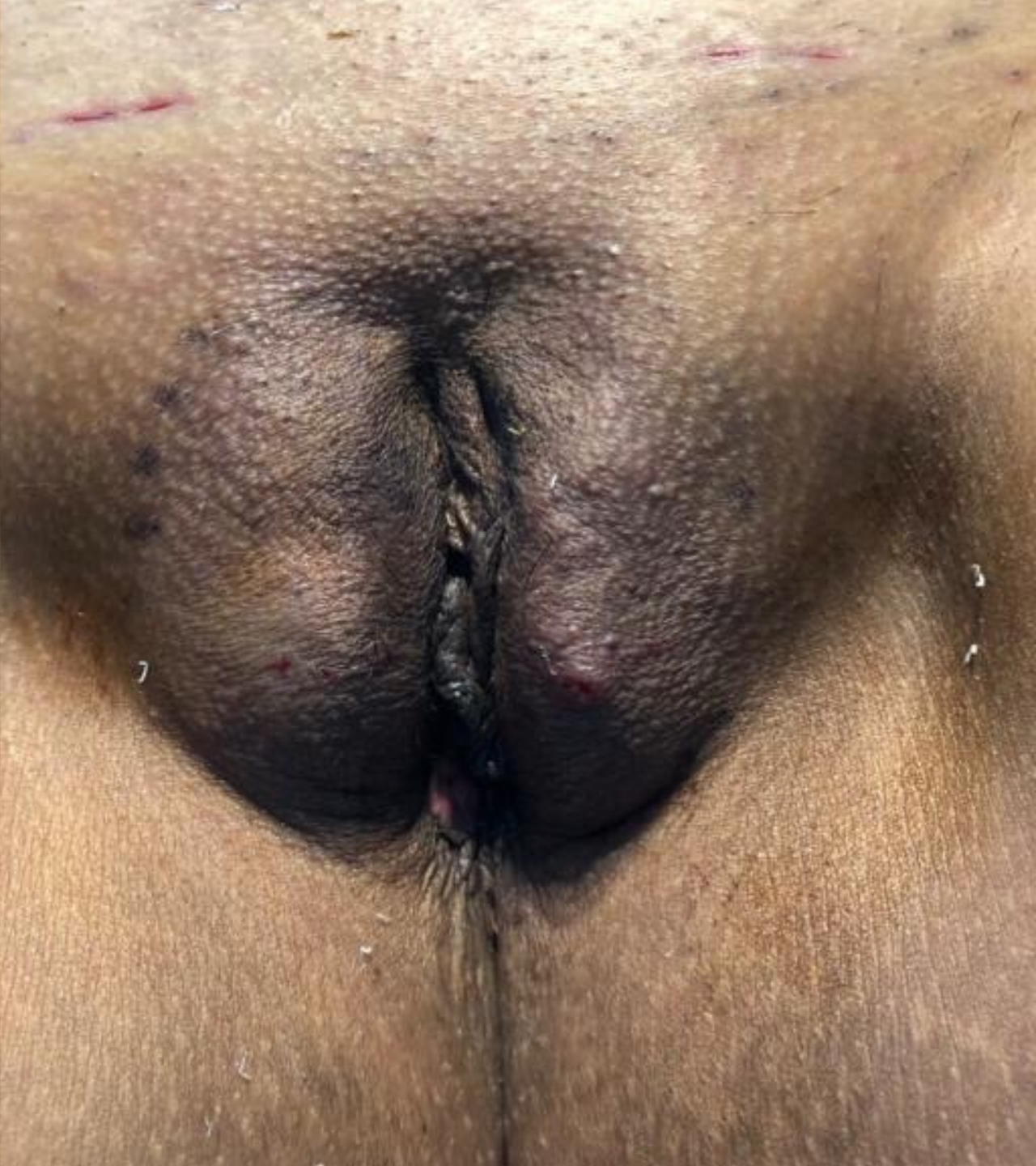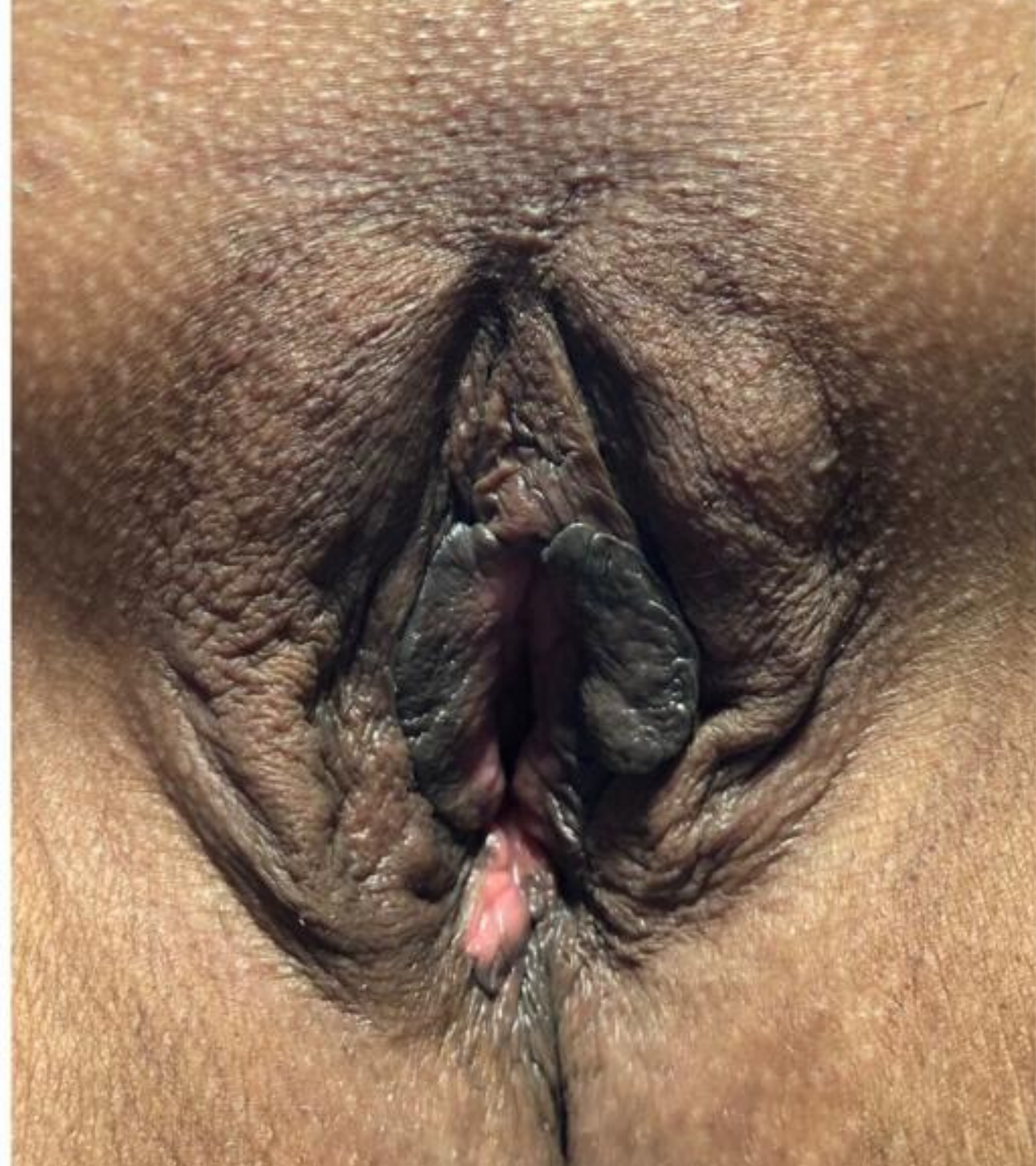


12 months



6 months





Özetlersek

“Selektif Enflamatuar Yanıt ” pek çok estetik prosedürün temelindeki prensiptir (lazer, chemical peels, microneedling).

Cildin kendini yenileyebilme kapasitesi çok yüksektir.

Askıları yerleştirdiğimiz zaman cildin, yeni kollajen sentezi yaparak kendini yenilemesini stimüle etmiş oluyoruz.

Bu tedaviye bir de PRP, nano fat de eklersek optimal bir rejuvenasyon tedavisi yapmış oluruz.

VULVA HYALÜRONİK ASİT UYGULAMALARI

1

to rejuvenate the
female external
genitalia

2

donating more
volume and
hydration to labia
majora

3

with a possible
positive influence on
the psychological
sphere

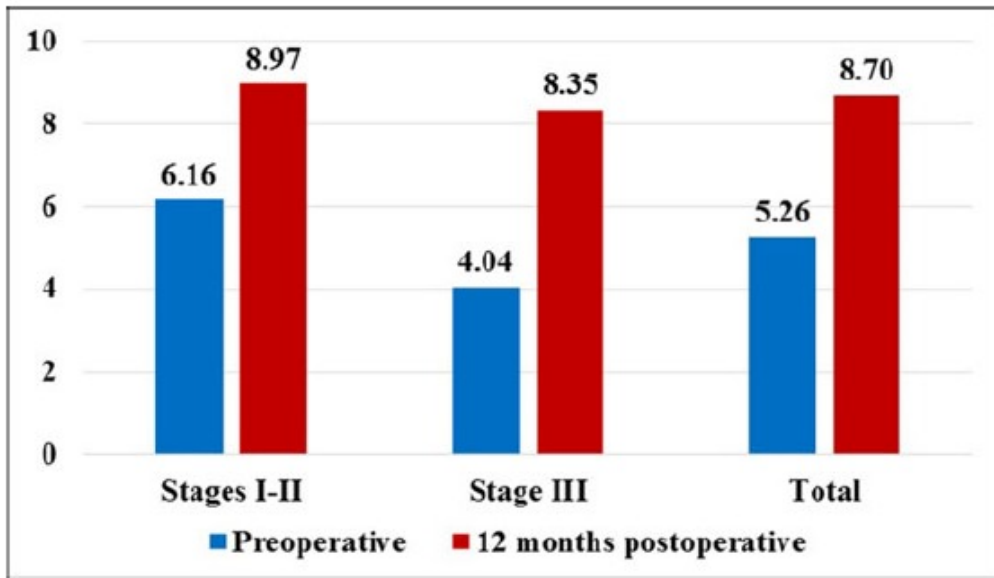


Figure 6. Patient evaluation of the treatment on the Global Aesthetic Improvement Scale (GAIS), preoperatively and 12 months postoperatively.

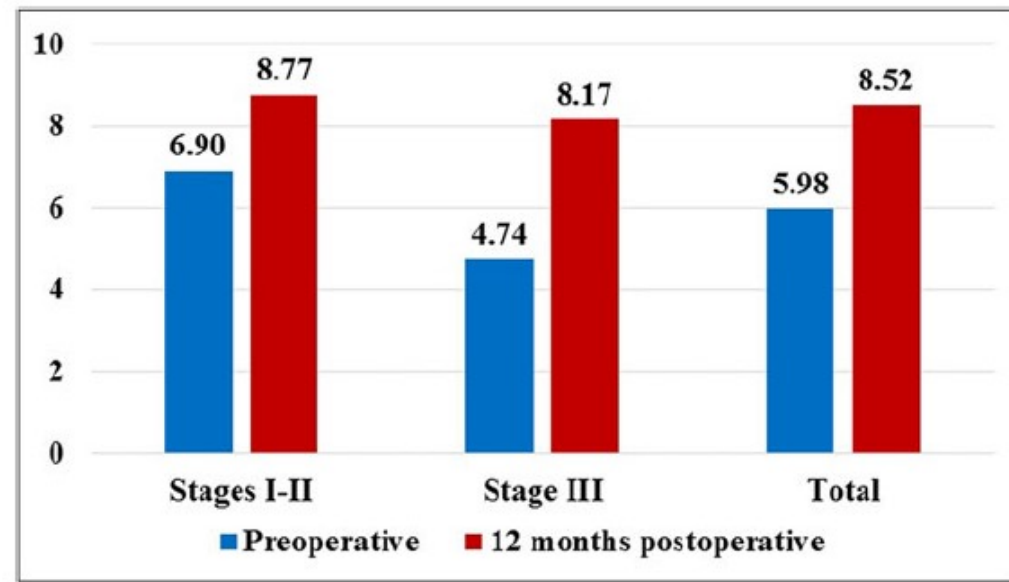


Figure 7. Doctor evaluation of the treatment on the Global Aesthetic Improvement Scale (GAIS) preoperatively and 12 months postoperatively.

Efficacy of injecting platelet concentrate combined with hyaluronic acid for the treatment of vulvovaginal atrophy in postmenopausal women with history of breast cancer: a phase 2 pilot study

Barbara Hersant, MD,^{1,2} Mounia SidAhmed-Mezi, PhD,¹ Yazid Belkacemi, MD, PhD,^{2,3}

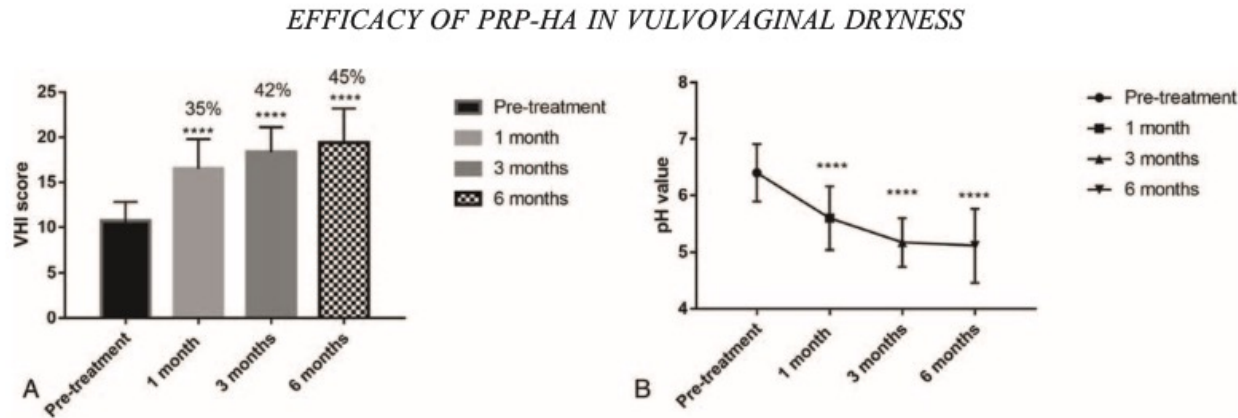


FIG. 3. (A) Time course of mean pH from baseline (pre-treatment) to 1 to 3 and 6 months after treatment. Bars represent standard deviation. **** $P < 0.0001$. (B) Mean VHI change and the percentage of improvement from baseline (pretreatment) to 1 to 3 and 6 months after treatment. Results represent mean SD (standard deviation). **** $P < 0.0001$. VHI, Vaginal Health Index.

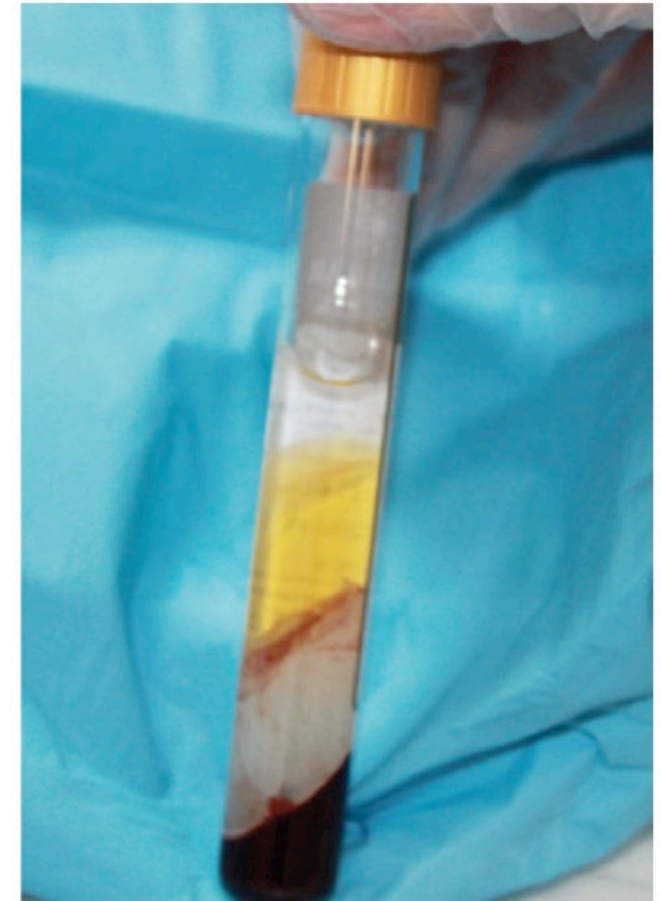


FIG. 1. Platelet-rich plasma combined with hyaluronic acid (PRP-HA) preparation with cellular matrix/BCT-HA kit. After centrifugation, the blood is fractionated: the red blood cells are trapped under the gel, and cellular elements settle on the surface of the gel. Hyaluronic acid is positioned on top of PRP. By gently inverting the Regen-BCT HA tube several times, proceed to the resuspension of the cellular deposit in the supernatant, and the homogenization of hyaluronic acid with PRP. About 4 mL of PRP-HA mix will be obtained for each tube. BCT-HA, blood cell therapy-hyaluronic acid.

Participants' satisfaction

We used a VAS to assess participant satisfaction. The participants were satisfied, with a mean score 6 months after treatment of 7.05 ± 1.69 . When asked, "Would you like to repeat the injections?" to maintain the effects over time, 19 out of 20 participants responded positively.

Concerning how well participants tolerated the treatment, the mean score on the VAS for pain during the injections was 5.46 ± 1.98 , and no adverse events were reported.

TABLE 2. Improvement in parameters of Vaginal Health Index after treatment

	Pretreatment (mean \pm SD)	1 mo (mean \pm SD)	3 mos (mean \pm SD)	6 mos (mean \pm SD)
Elasticity	2.25 ± 0.78	3.05 ± 0.51^a	3.6 ± 0.50^a	3.75 ± 0.44^a
Fluid volume (pooling of secretion)	2.05 ± 0.75	3.35 ± 0.81^a	3.6 ± 0.99^a	4.2 ± 0.61^a
pH	6.4 ± 0.5	5.6 ± 0.56^a	5.17 ± 0.43^a	5.11 ± 0.65^a
Epithelial integrity	2.7 ± 1.12	3.3 ± 0.77 (NS)	3.6 ± 0.60^b	3.87 ± 0.57^a
Moisture	2.1 ± 0.78	3.8 ± 0.76^a	3.9 ± 0.55^a	4.4 ± 0.68^a
Total	10.7 ± 2.1	16.5 ± 3.28^a	18.35 ± 2.75^a	19.4 ± 3.8^a

NS, nonsignificant; SD, standard deviation.

^a $P < 0.0001$.

^b $P < 0.01$.

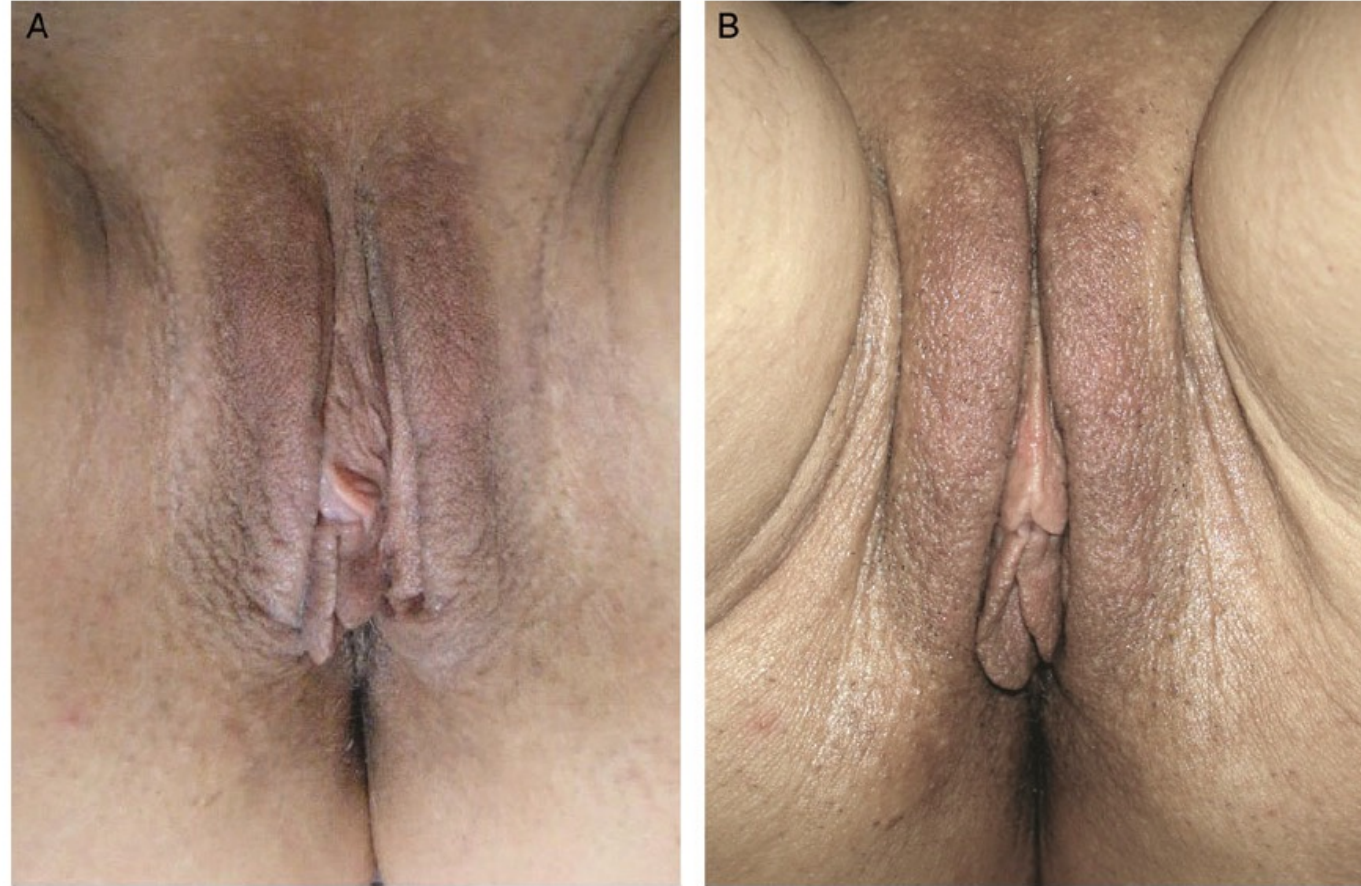
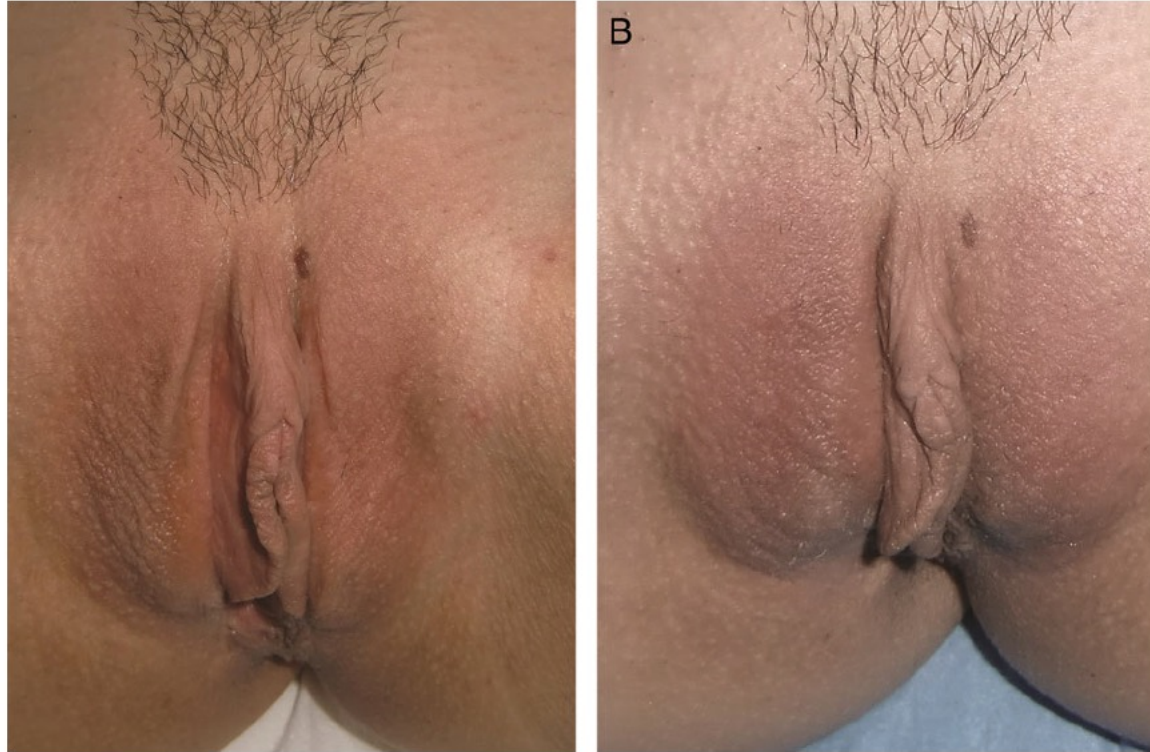
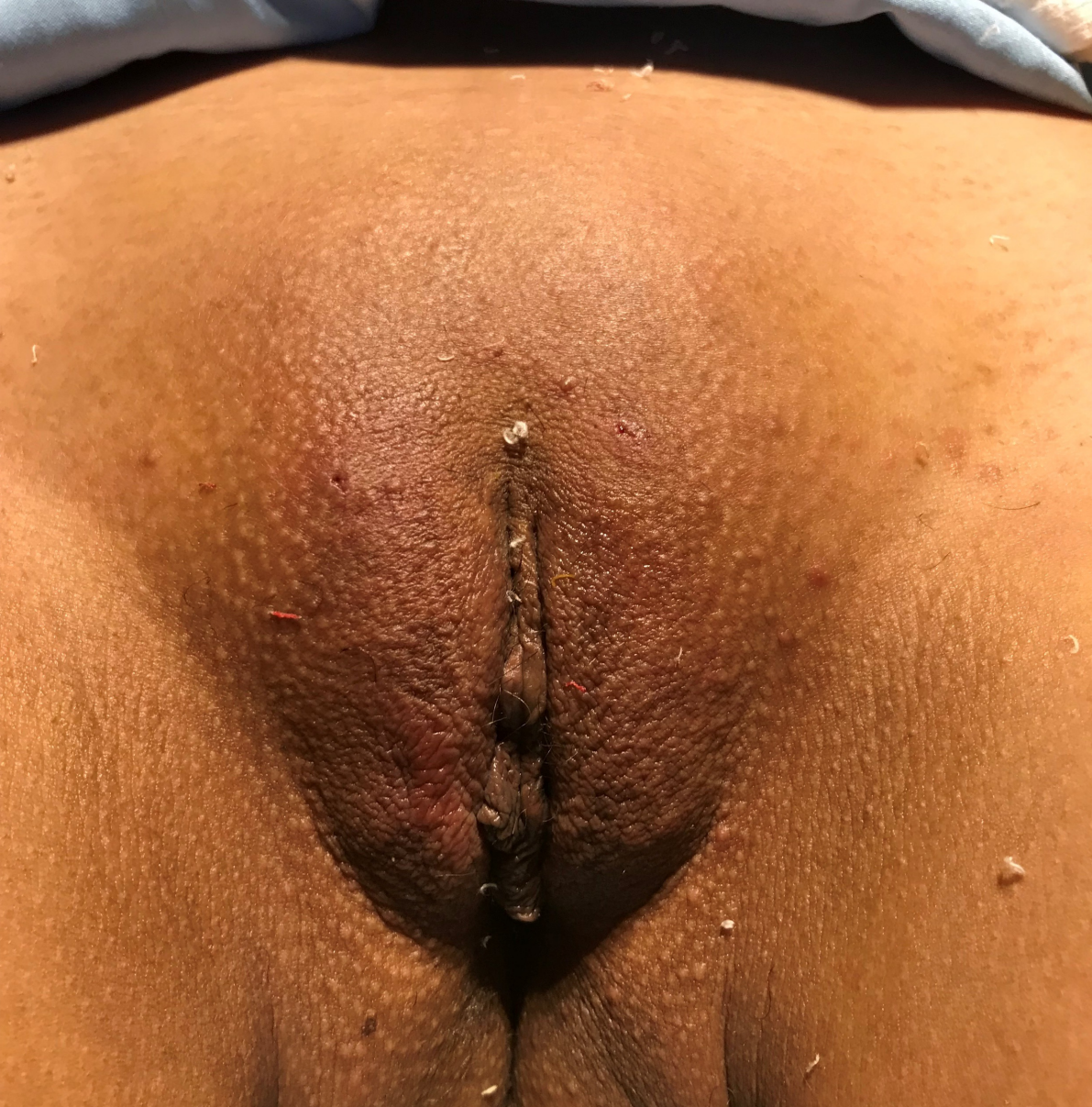
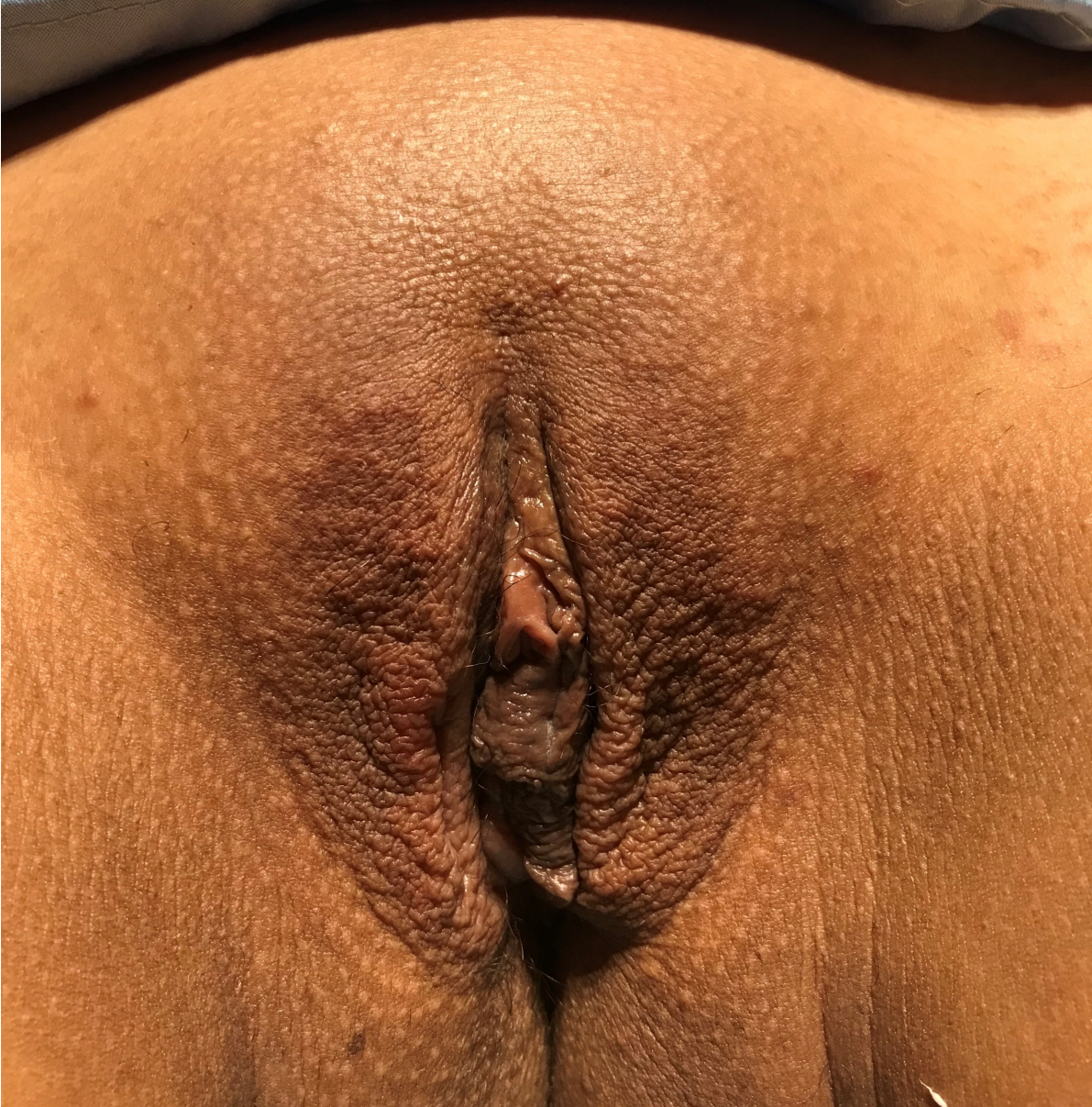Figure 4. A 63-year-old woman affected by moderate hypotrophy of labia majora. The patient received 19 mg/mL hyaluronic acid, 1 mL per part. At 6 months later a second treatment with 19 mg/mL hyaluronic acid was carried out (1 mL per part). (A) A preoperative photograph and the result at 12 months (B) from the first treatment are shown.

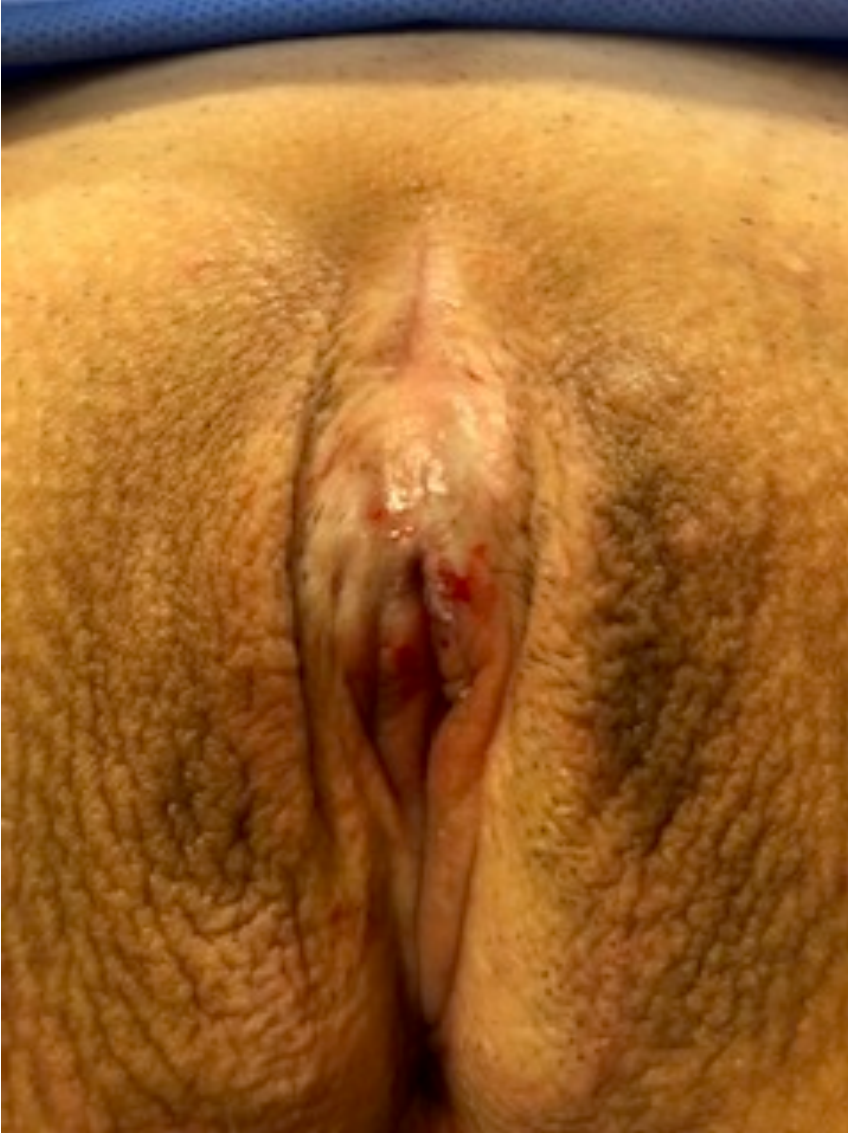

1 **Figure 5.** A 34-year-old woman affected by severe hypotrophy of labia majora. The patient was infiltrated with 21 mg/mL hyal-
1 uronic acid, 1 mL per part. At 7 weeks later, a second infiltration with 19 mg/mL hyaluronic acid was carried out (1 mL per part).
2 (A) A preoperative photograph and the result at 12 months (B) from the first infiltration are shown.

Lazer vulvar tightening& HA Dolgu



Tedavi öncesi/ 32011664



Lichen simplex: Nd Yag Laser + PRP





