

Pelvik Nöropatik Ağrı Sendromları ve Etiyolojisi

Dr. Kiper Aslan

Bursa Uludağ Üniversitesi Tıp Fakültesi
Kadın Hastalıkları ve Doğum Anabilim Dalı



Plan

```
graph TD; Plan[Plan] --- A[Ağrı Sendromları]; A --> B[Endometriozis & Ağrı]; B --> C[Nadir Durumlar]; C --> D[Sonuç];
```

**Ağrı
Sendromları**

**Endometriozis &
Ağrı**

Nadir Durumlar

Sonuç

Ađrı Sendromları

Somatik & Visseral Ađrı?

- **Endometriozis**
- Vulvodini
- Pudental Nöralji
 - Alcock's Kanalı Sendromu
- Piriformis Sendrom
- İyatrojenik Radikulopatiler
- Sakrokoksigeal Teratom
- Pelvik Schwannoma

TORTURE

GRIPS

“

Like torture. Like somebody is gripping, squeezing, cutting, prodding, stabbing you inside, and won't let go.

”

Bodyform

#PAINSTORIES

WOMBWAR

“

On a bad day, it's no man's land. Barbed wire, bombs, gunfire... Shooting pains down my body mean standing up is not an option.

”

Bodyform

#PAINSTORIES

PAIN
DROWN

“

I'm drowning in pain, I am trapped - yet I'm still fighting. My pain is unpredictable and uncontrollable. Sharp. Shooting. Sickening.

”

Bodyform

#PAINSTORIES

ORGANFULSE


“

It's like drowning, ton of bricks on my chest, my organs in a box being squashed together.


”

Bodyform


#PAINSTORIES



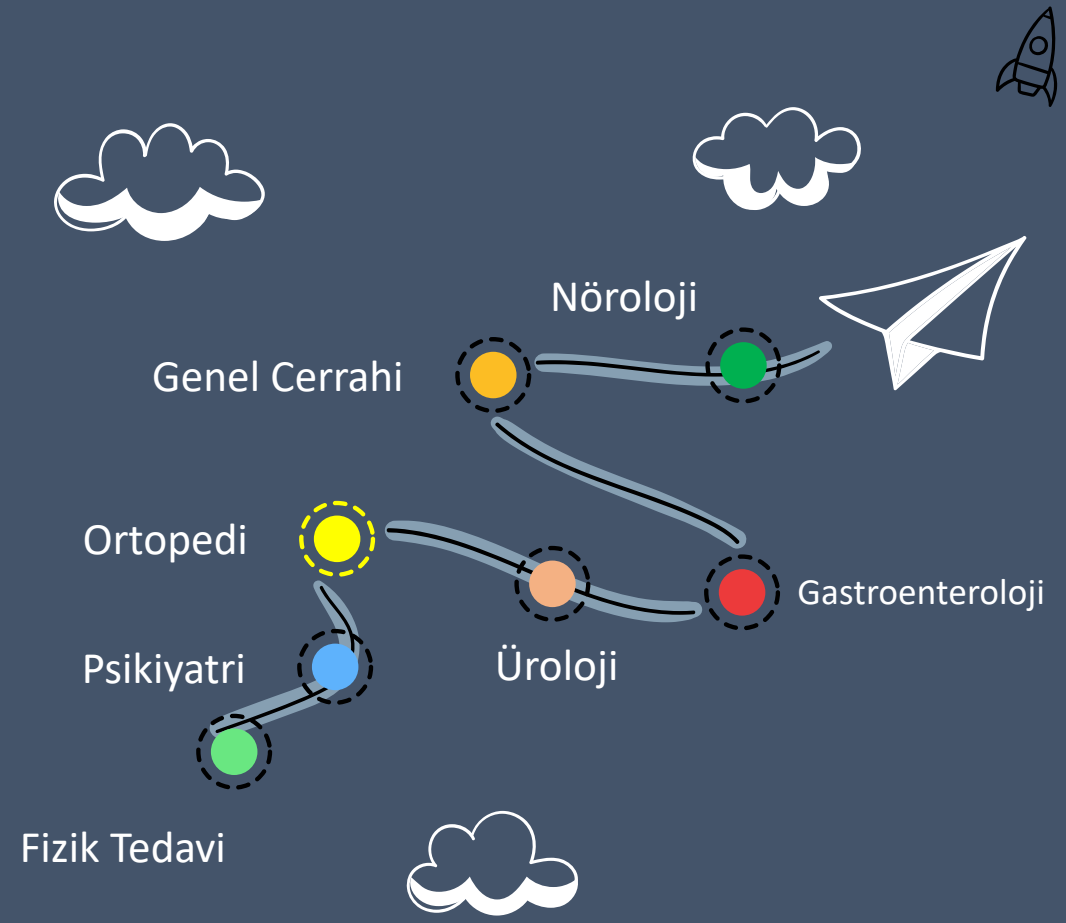
Tüm Populasyon



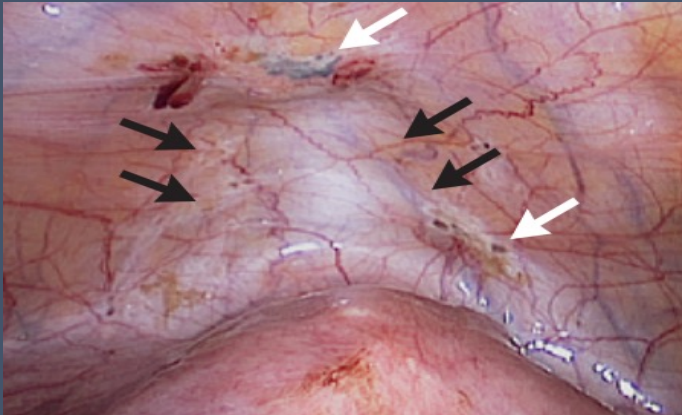
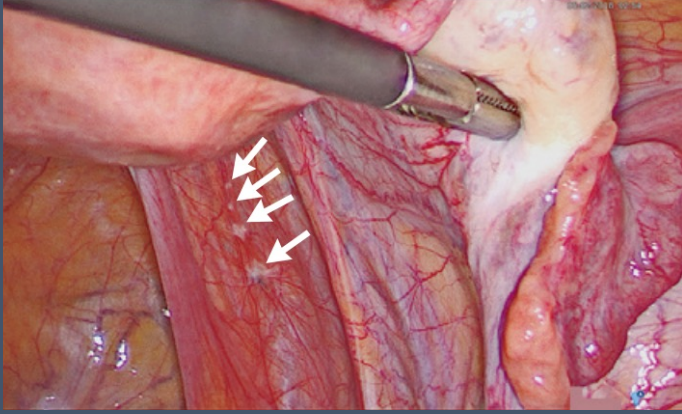
İnfertil Populasyon



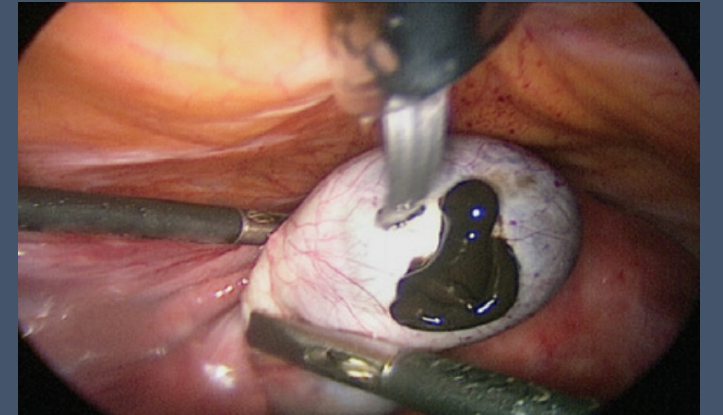
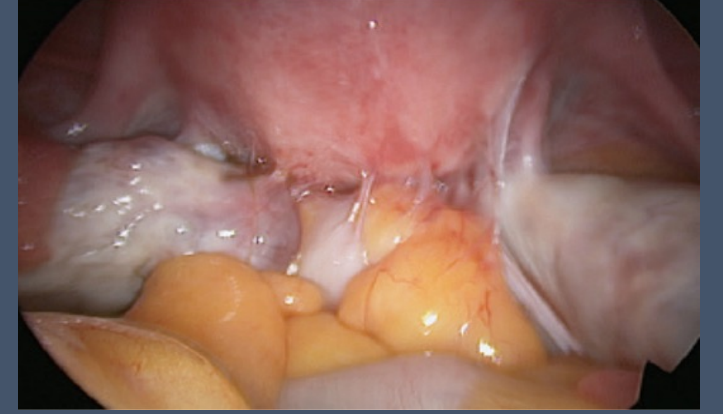Pelvik Ağrı



Semptomlar



- Dismenore
- Kronik Pelvik Ağrı
- Disparoni
- Diskezi
- Dizüri
- Somato-Sensöryel Artış



Postulated Origins of Endometriosis

Retrograde menstruation
(endometriotic lesions)

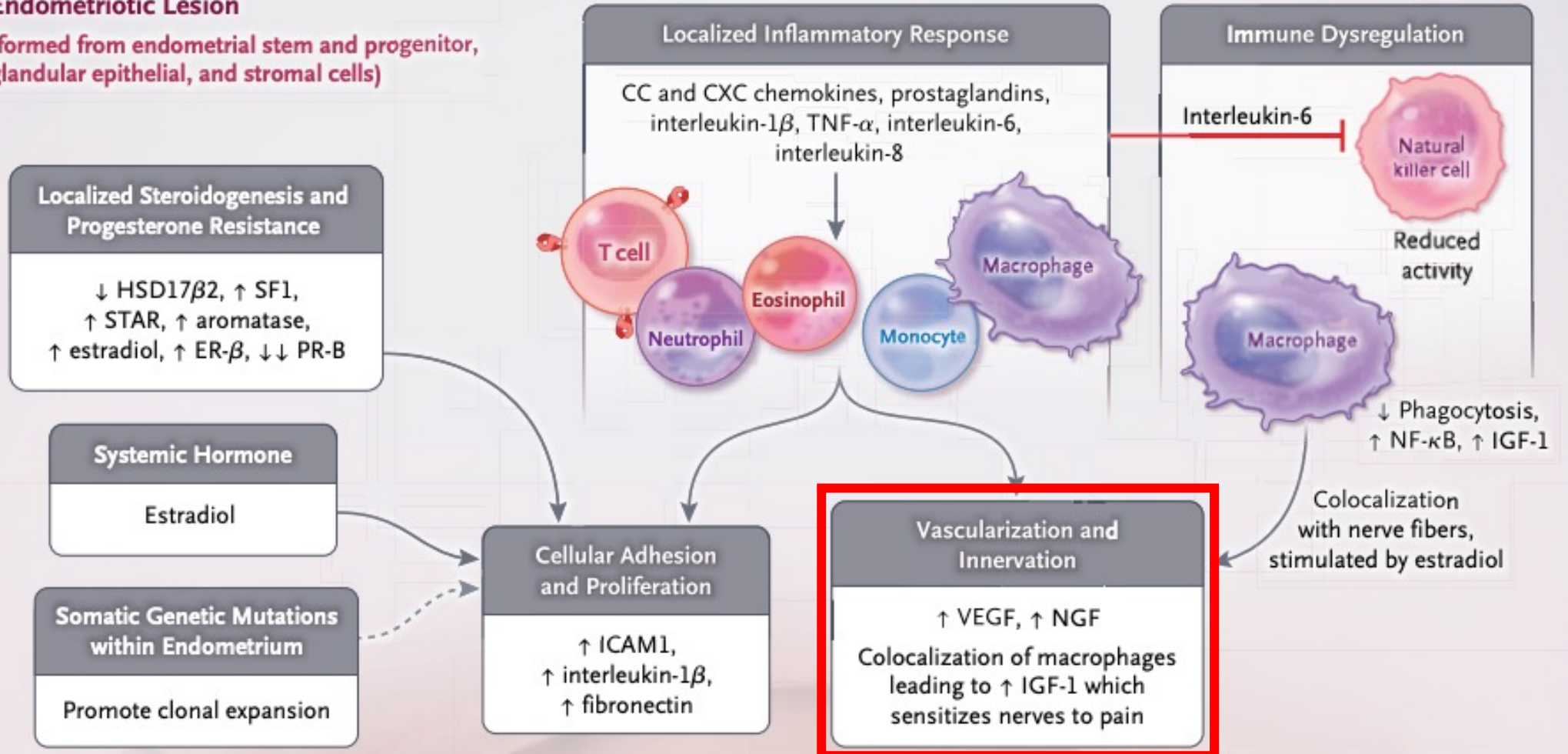
Coelomic metaplasia
(peritoneal lesions)

Vascular and
lymphatic metastasis
(extrapelvic lesions)

Zondervan et al. 2020, NEJM

Endometriotic Lesion

(formed from endometrial stem and progenitor, glandular epithelial, and stromal cells)

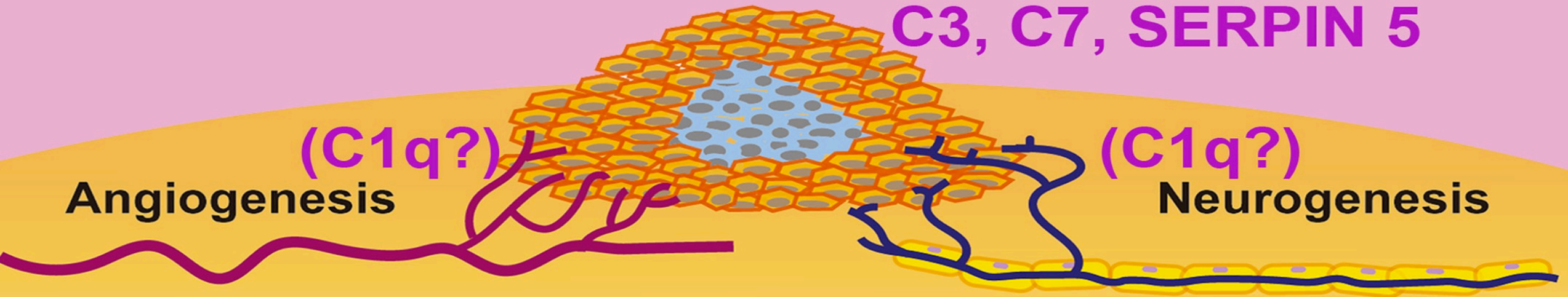


Peritoneal Liquid

C1q, MBL, C1INH, iC3b, C3c, C4, and sC5b-9

Endometriotic cells

C3, C7, SERPIN 5



Angiogenesis

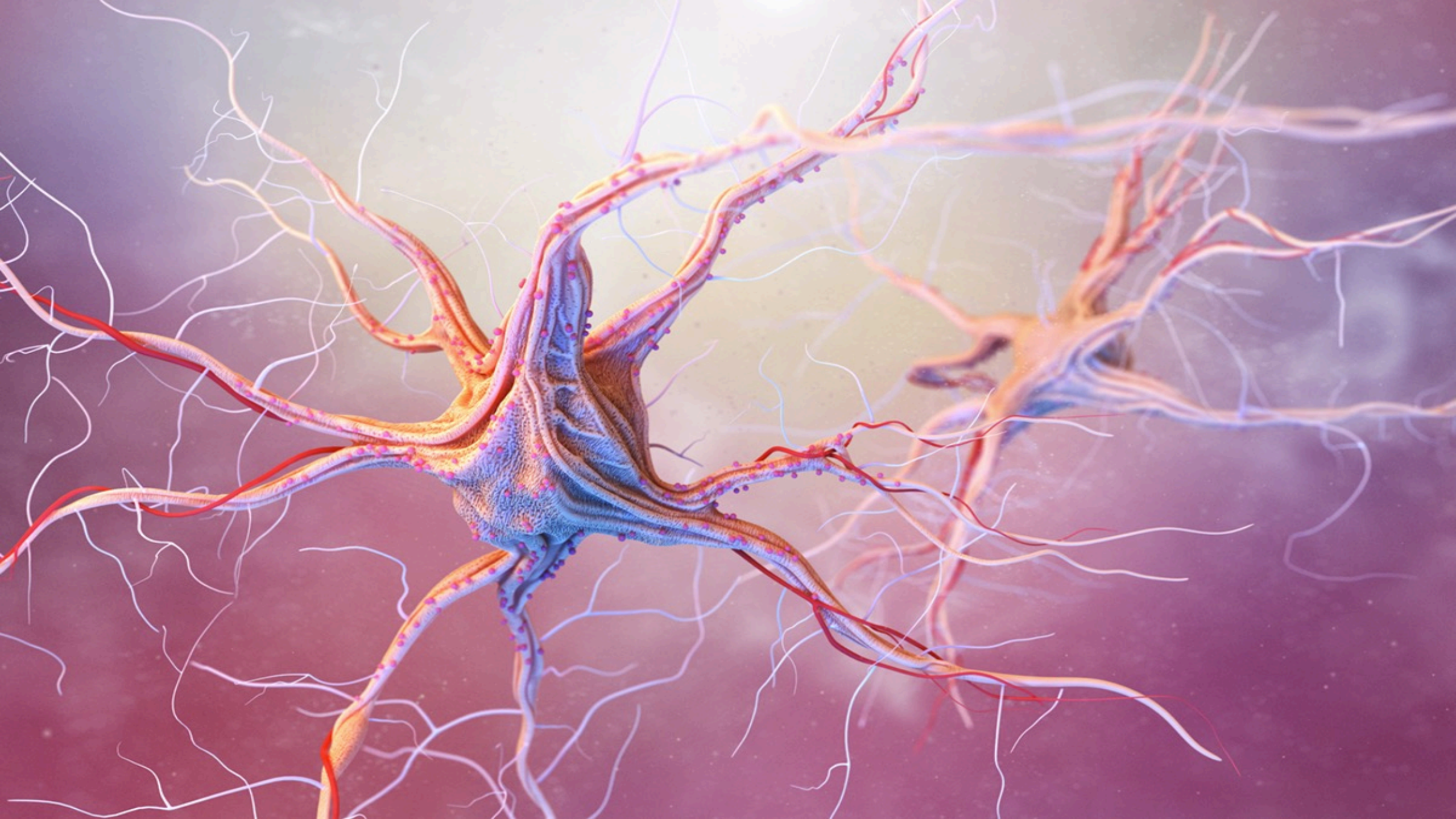
(C1q?)









(C1q?)

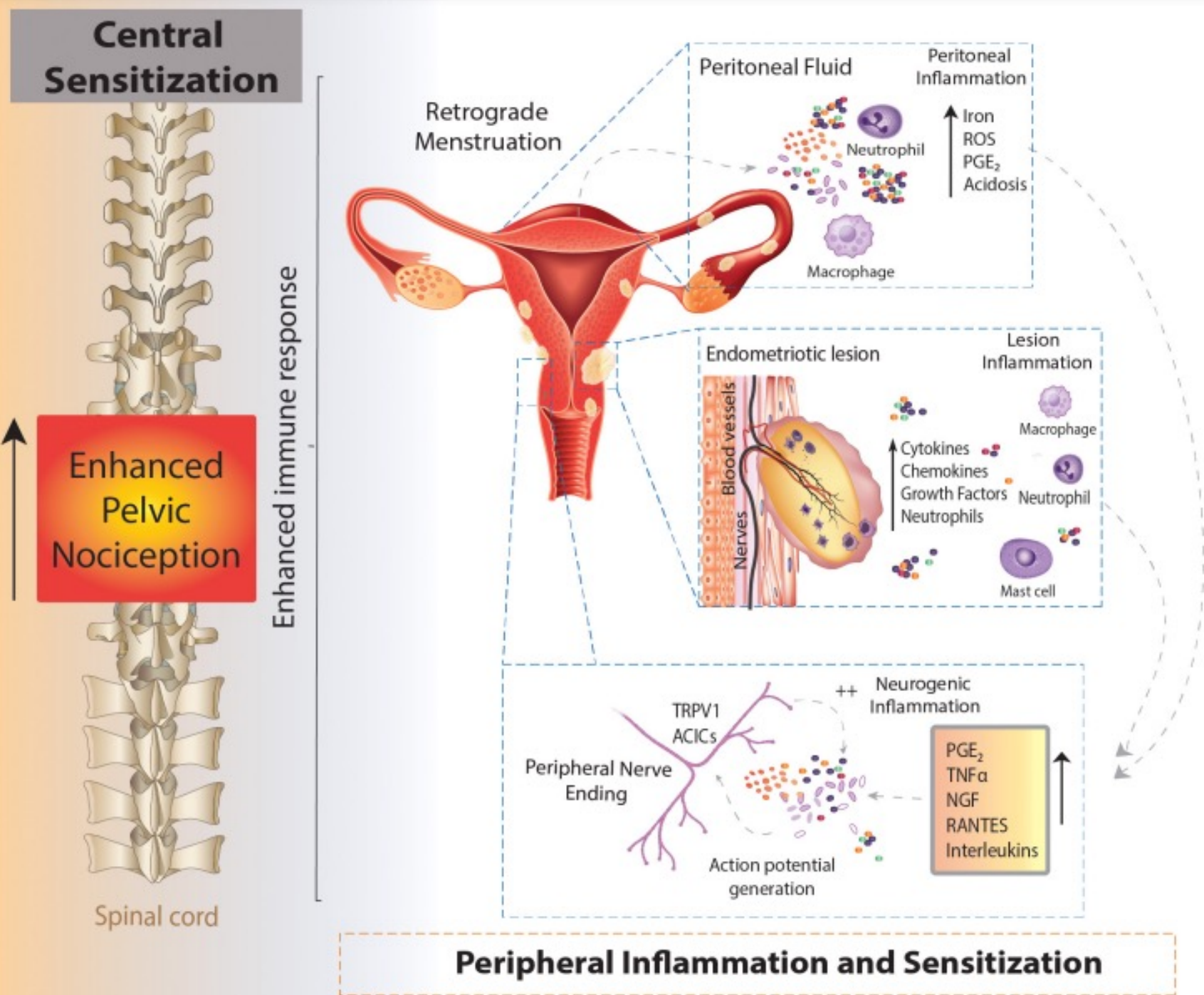
Neurogenesis

Inflammatory Environment

C3, C7, CFD, CFB, CFH



Sinir Lifi	Görev	Myelin	Çap (micrometre)	İletim Hızı (m/s)		
A - Alfa	Propriyosepsiyon	+	13-20	80-120		
A- Beta	Dokunma	+	6-12	35-90		
A - Delta	Ağrı - Akut	+	1-5	5-40		
C	Ağrı - Kronik	-	0.2-1.5	0.5-2		



İnflamasyon

Nörojenik İnflamasyon

Periferik Sensitizasyon

Santral Sensitizasyon

Çapraz Organ Reaksiyonu

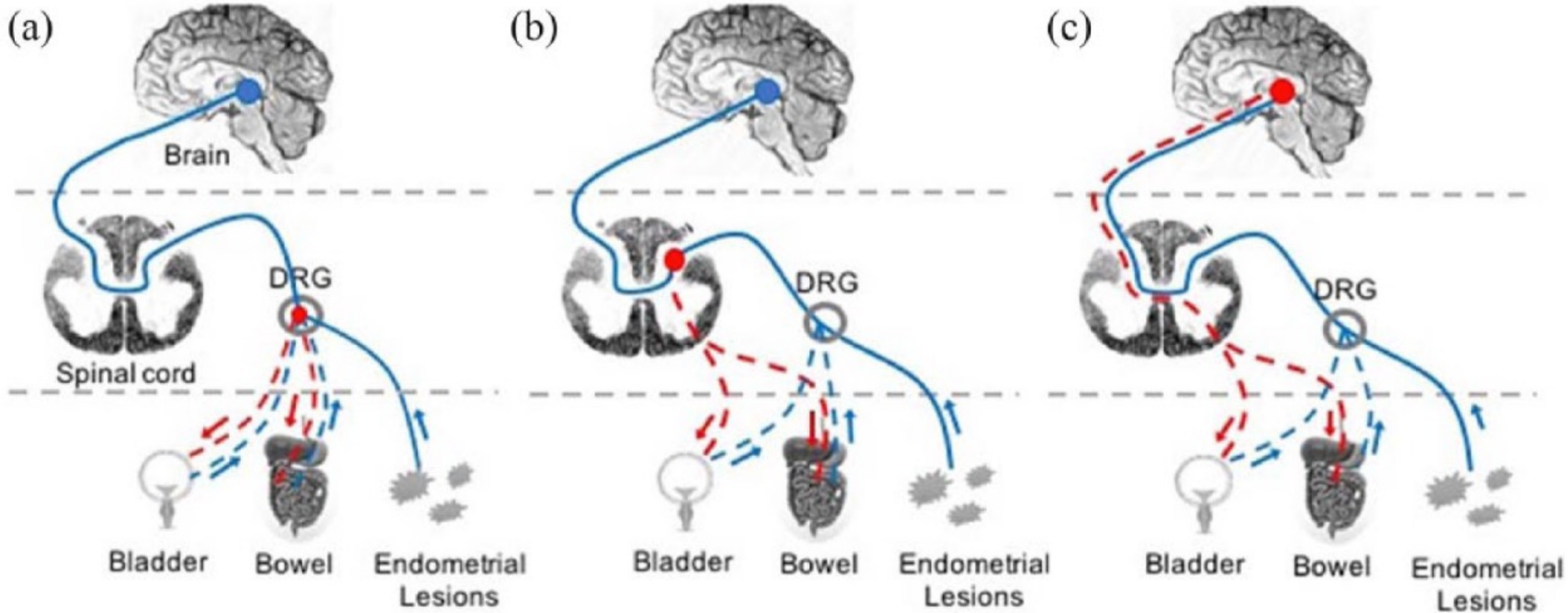


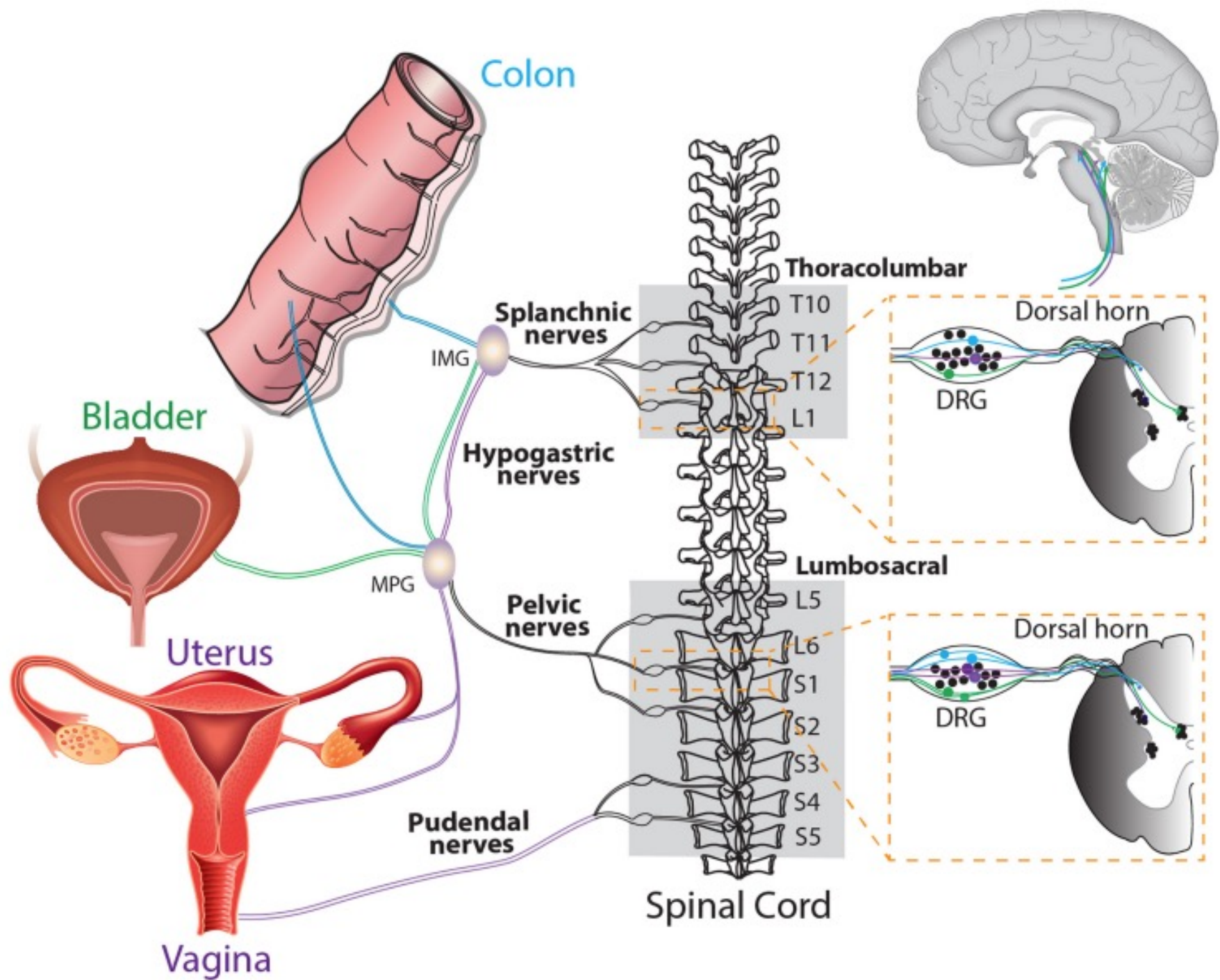
Table 1. Evidence for pelvic organ cross-talk – in rat models.


Source of origin	Changes in unaffected organ	References
Endometriosis	Vaginal hyperalgesia	Berkley et al. ⁴⁰ Cason et al. ⁴³ Berkley et al. ⁴² McAllister et al. ⁴¹ McAllister et al. ²³ Morrison et al. ⁴⁶
Endometriosis	Lower micturition thresholds and increased vascular permeability in bladder	
Endometriosis and urinary stone	Increased pain-response and muscle hyperalgesia	Giamberardino et al. ⁴⁵
Endometriosis	Increased pain-response to colorectal distension	Wang et al. ²⁰ Chen et al. ¹⁹
Uterus	Increased vascular permeability in bladder and increased urethra-reflex activity	Winnard et al. ⁴⁴ Peng et al. ⁴⁷
Bladder	Decreased uterine contraction	Dmitrieva et al. ⁴⁸ Dmitrieva et al. ⁴⁹

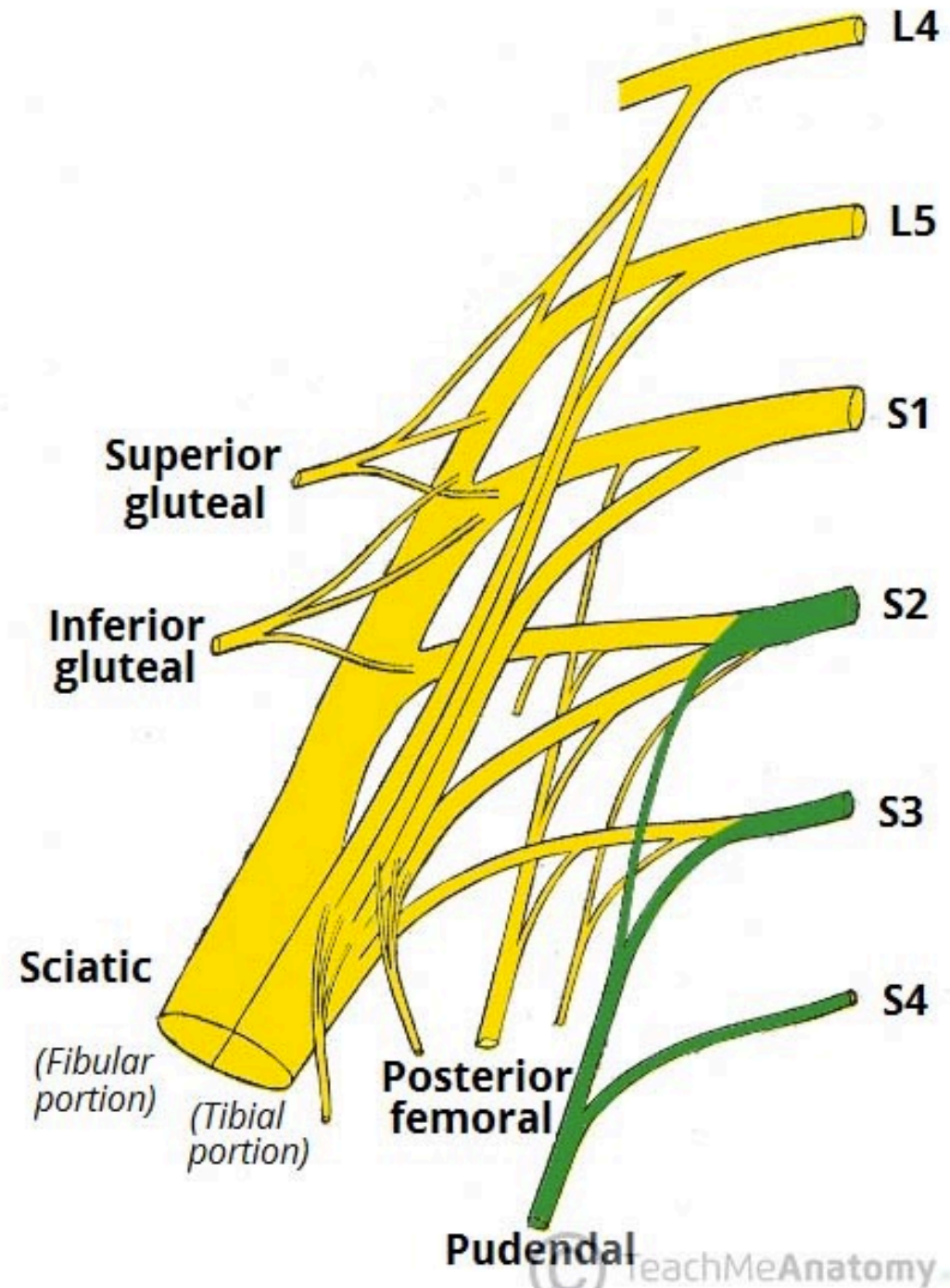
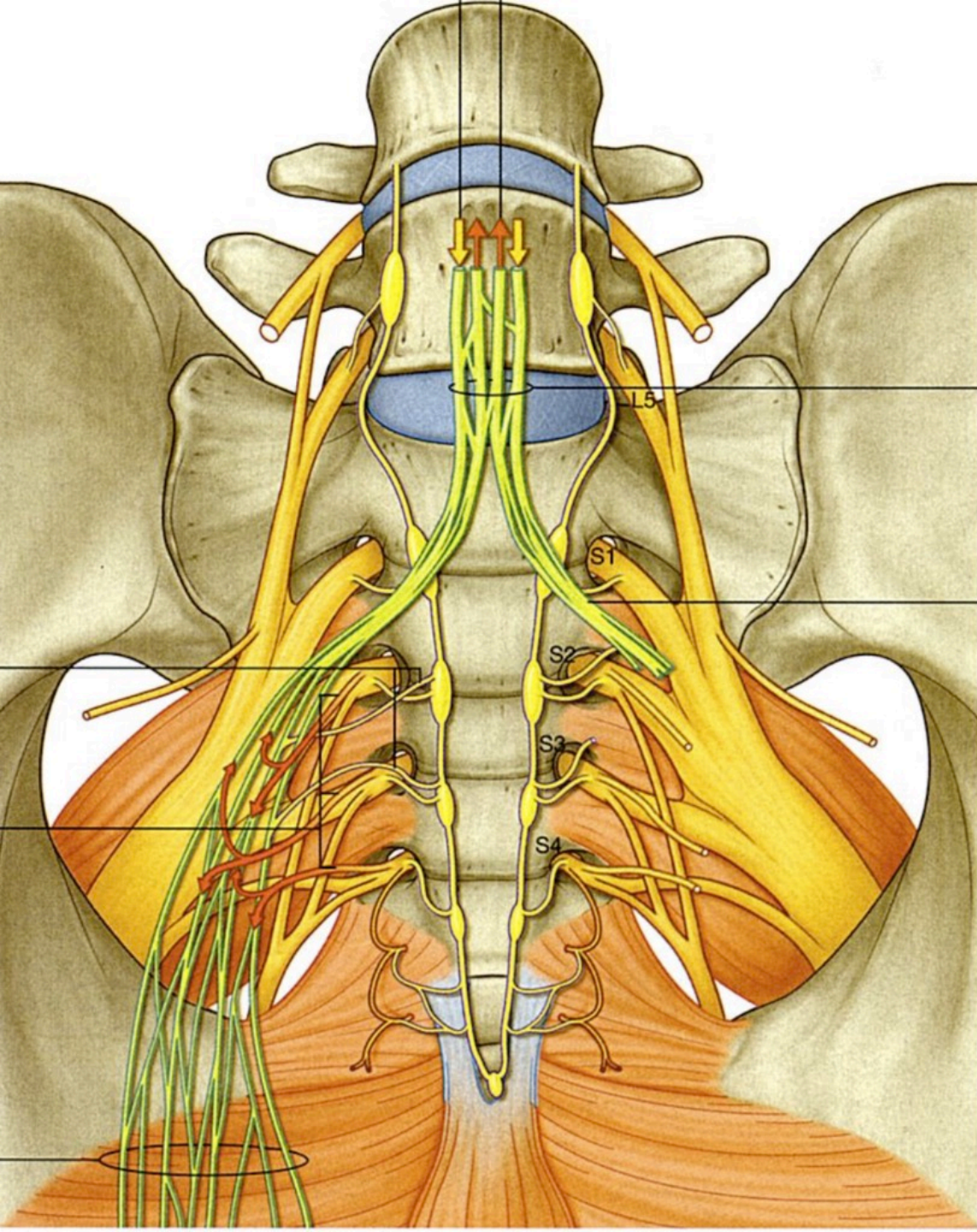
Table 2. Evidence for pelvic organ cross-talk – human studies.

Source of origin	Changes in unaffected structures	References
Endometriosis	Lower pain thresholds to rectal distention	Issa et al. ⁸
Endometriosis and urinary stone	Lower pain thresholds and more urinary colic events More urinary and menstrual pain and lumbar and abdominal hyperalgesia	Giamberardino et al. ⁵⁰ Giamberardino et al. ⁵¹
Endometriosis and IBS	More intestinal and menstrual pain and abdominal and pelvic muscle hyperalgesia	Giamberardino et al. ⁵¹
Endometriosis	Higher bladder-base tenderness Higher pelvic-floor tenderness	Nourmoussavi et al. ⁵⁶ Young et al. ⁵⁷
Endometriosis	General hyperalgesia, as pain thresholds throughout the body were lower	He et al. ⁵² Bajaj et al. ⁵³ As-Sanie et al. ⁵⁴ Stratton et al. ⁵⁵

IBS: irritable bowel syndrome.









ATL

-0

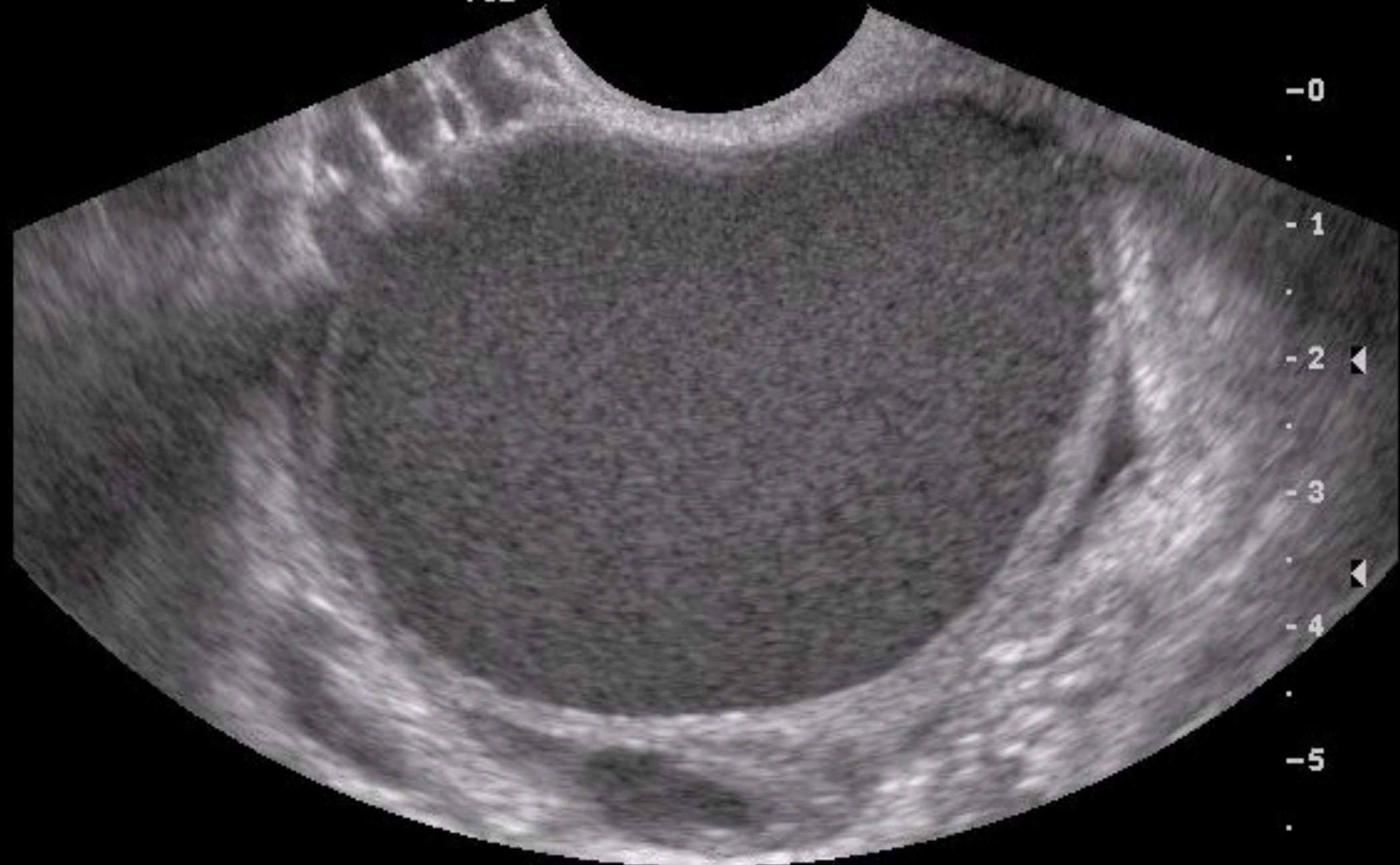
-1

-2

-3

-4

-5



Nosiseptif Ağrı

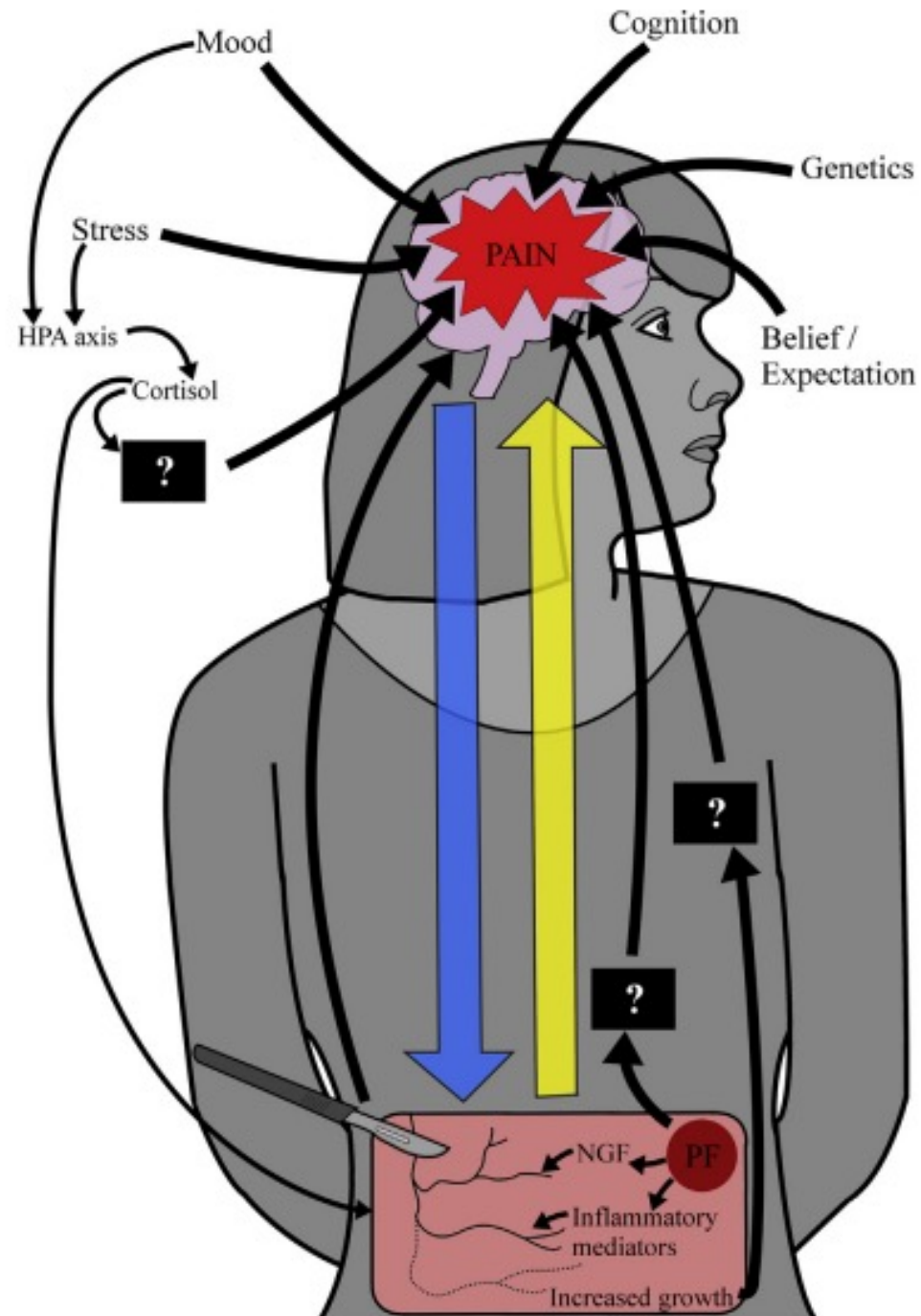
İnflamatuvar Ağrı

Nöropatik Ağrı

Santralize Ağrı

Çapraz Organ Reaksiyonu

Mood Değişiklikleri



Hiperalezi


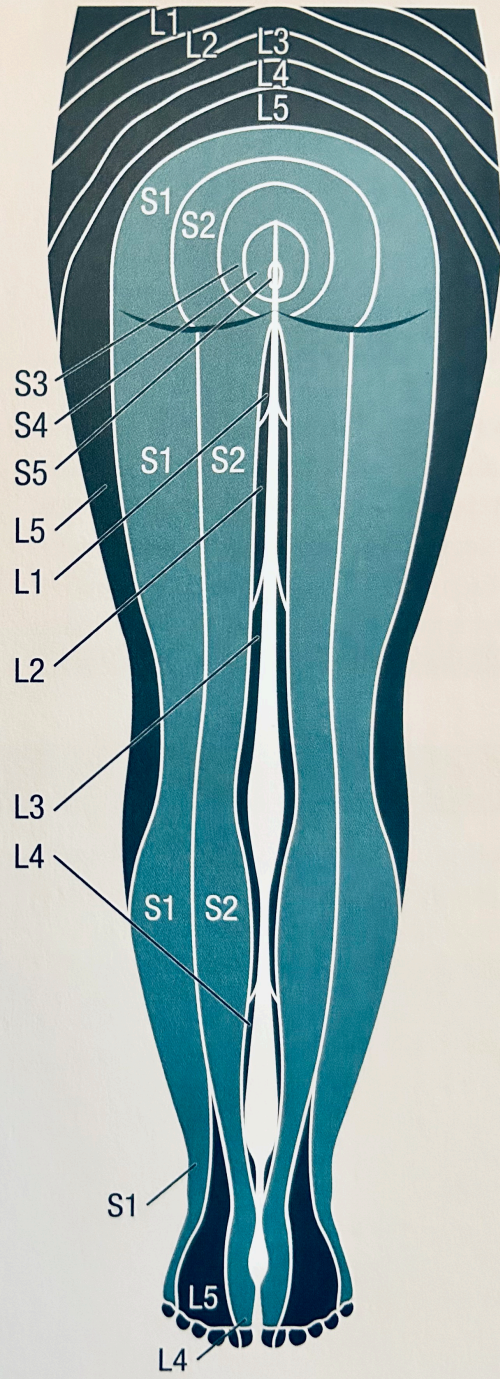
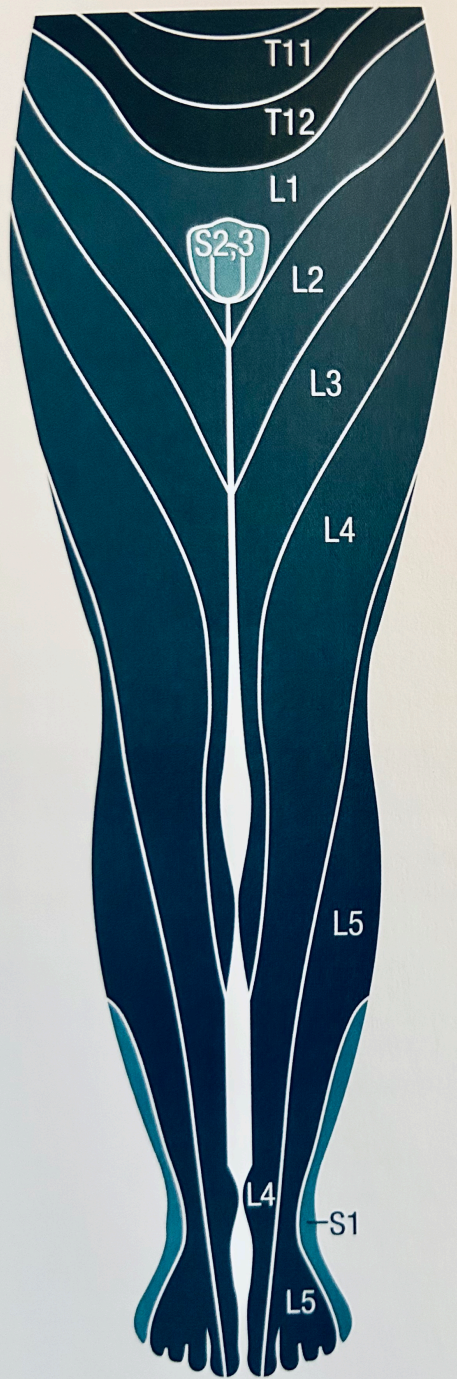
Allodini

Diskezi

Dizüri

Disparoni

Dismenore



Genital Ağrı	Genitofemoral S2-S3
Anal Ağrı	Pudental S2-S3
Perineal Ağrı	Pudental S2-S3-S4
Koksigeal Ağrı	Pudental S2-S3-S4
Lumbal Ağrı	L5-S1-2
Gluteal Ağrı	S1-S2
Dorsal Bacak	S1-S2
Diz Ön	L5

Ađrı Sendromları

Somatik & Visseral Ađrı?

- Endometriozis
- **Vulvodini**
- Pudental Nöralji
 - Alcock's Kanalı Sendromu
- Piriformis Sendrom
- İyatrojenik Radikulopatiler
- Sakrokoksigeal Teratom
- Pelvik Schwannoma

Vulvodini

- Allodini
- Uyuşma
- Hipersensitivite
- Elektriklenme
- Bıçak batar gibi
- Sıcaklık hissi
- IBS benzeri bulgular
- Disparoni – Penetrasyon bozukluğu

VULVODYNIA SYMPTOMS & SIGNS

SIGNS GENERALISED

- 

Constant pain
- 

Painful sexual intercourse
- 

Painful prolonged sitting

SIGNS LOCALISED

- 

Painful tampon insertion
- 


Pain wearing fitted pants
- 

Irritation, burning & stinging

 London Pain Clinic

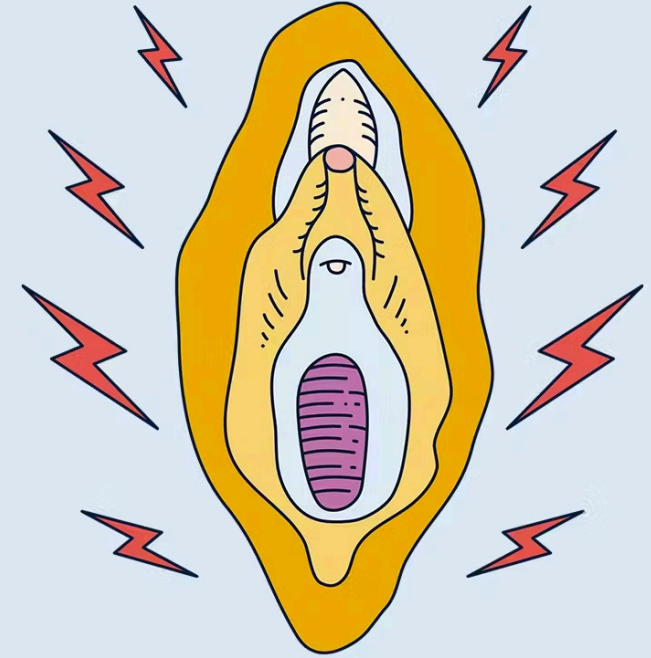
Ekartasyon Tanısı

Kontakt Dermatit	Pemfigo
Aftoz Ülser	Liken Planus
Atrofi	Liken Sklerozis
Bartholin Absesi	Podofilin Yan Etkisi
Kandida	Uretral Patolojiler
Karsinom	Sjogren
Endometriozis	Travma
Herpes Simpleks	VAIN



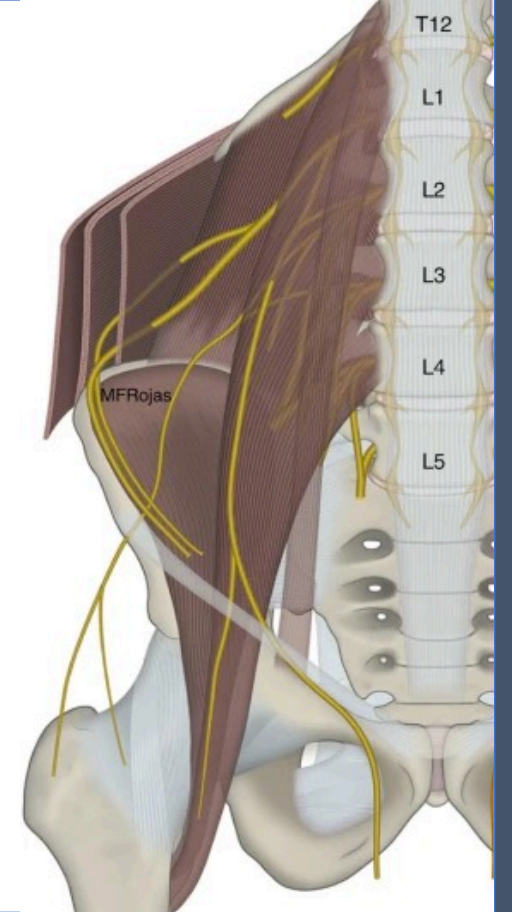
Vulvodini – Nöropatik Etiyolojiler

- Pudental Nöralji
- Diyabetik Nöropati
- Post-herpetic Nöralji
- Otoimmün, inflamatuvar hastalıklar
- MS...
- ...



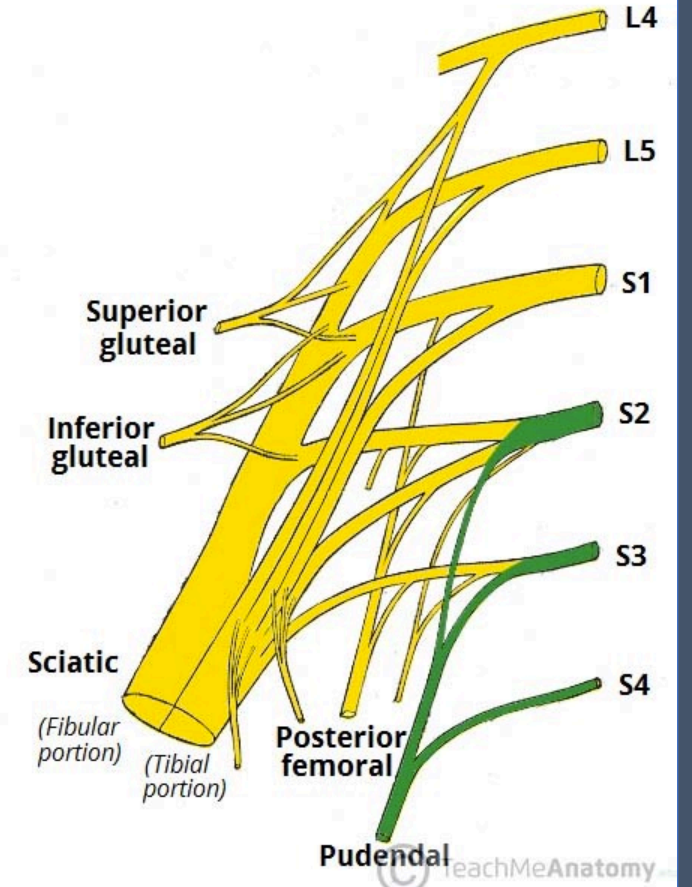
Nöropatik Vulvodini

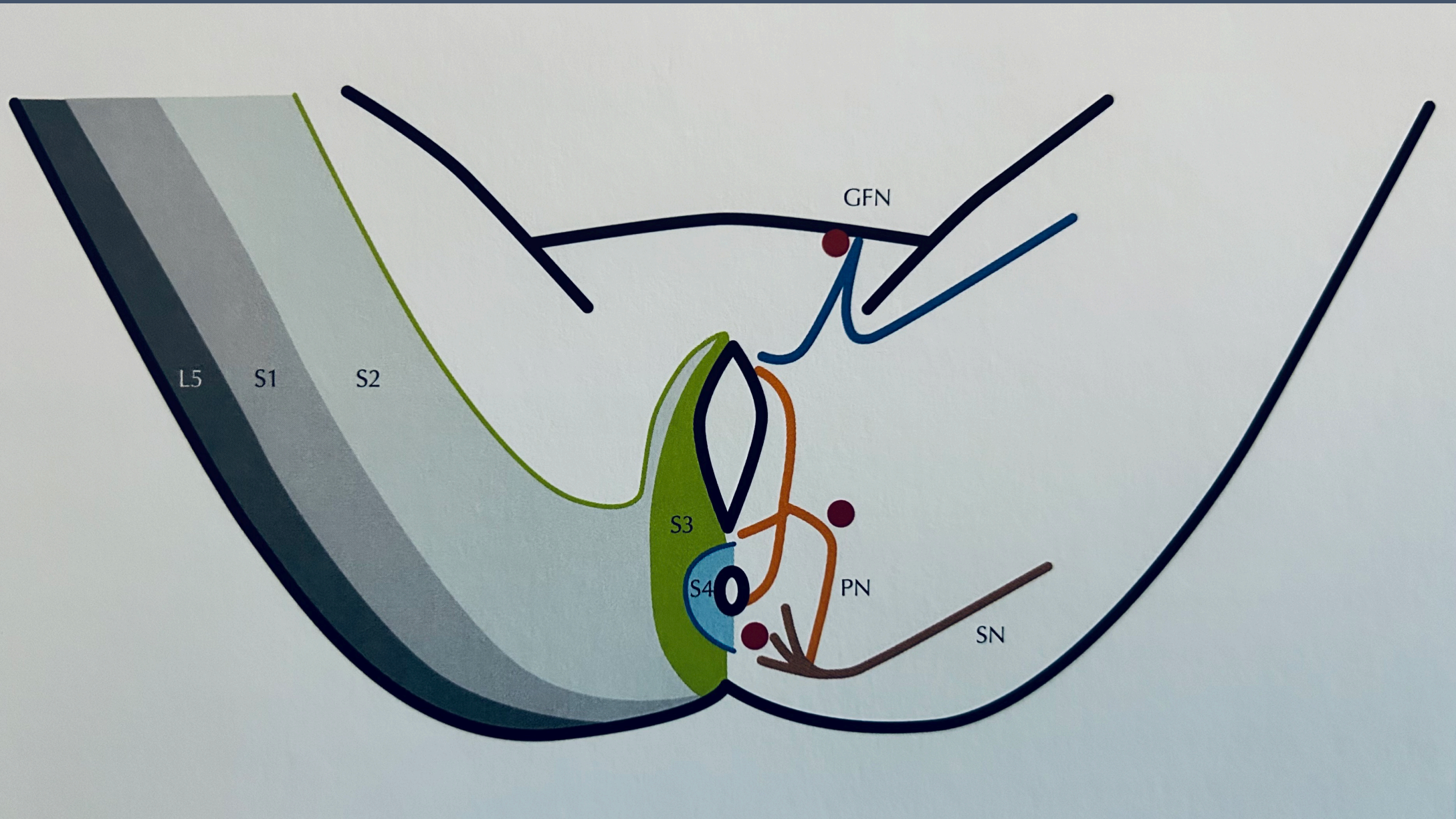
- Pudental Sinir – Distal
 - Vajinal Doğum ya da proctolojik işlem sonrası
 - Trigger point (+)
 - Ek organ disfonksiyonu yoktur
 - Lidokain ile iyileşme mevcut
 - Tedavisi – botox ya da cerrahi
- Genito-femoral Sinir
 - İnguinal alan ile birlikte uyluğa yansıyan ağrı
 - Anterior vulvodini
 - Semptomlar sadece sensöryel
 - İnguinal alan cerrahileri sebep olabilir (apendektomi, herni, trokar girişi etc.)



Pudendal Nöralji (Alcock's Syndrome)

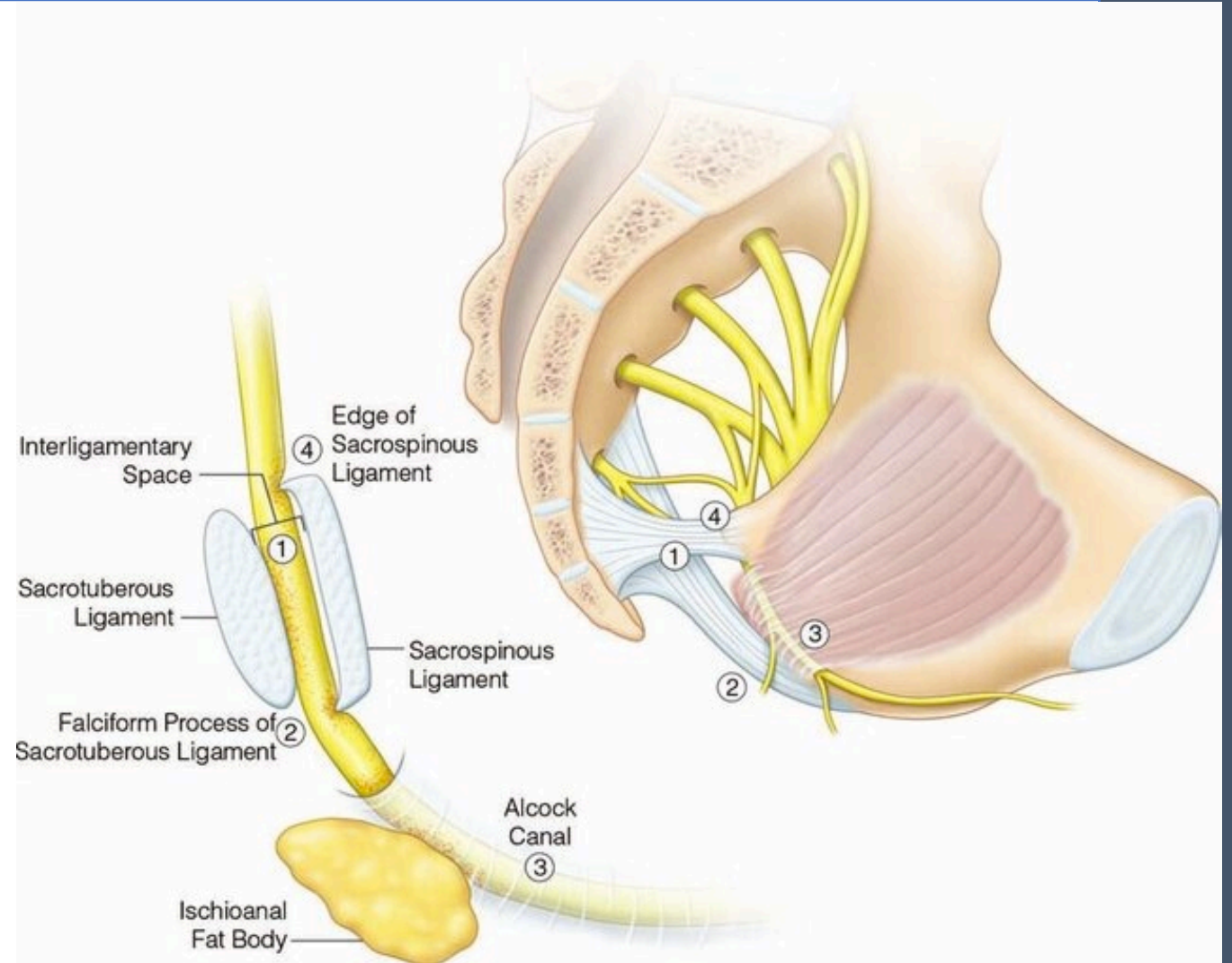
- Tüm innerve edilen alanı etkileyebilir
 - Oturma ile şiddetlenir
 - Sadece duysal değil organ disfonk. olabilir
 - Uriner
 - GIS
 - Seksüel
- (S2-S4)

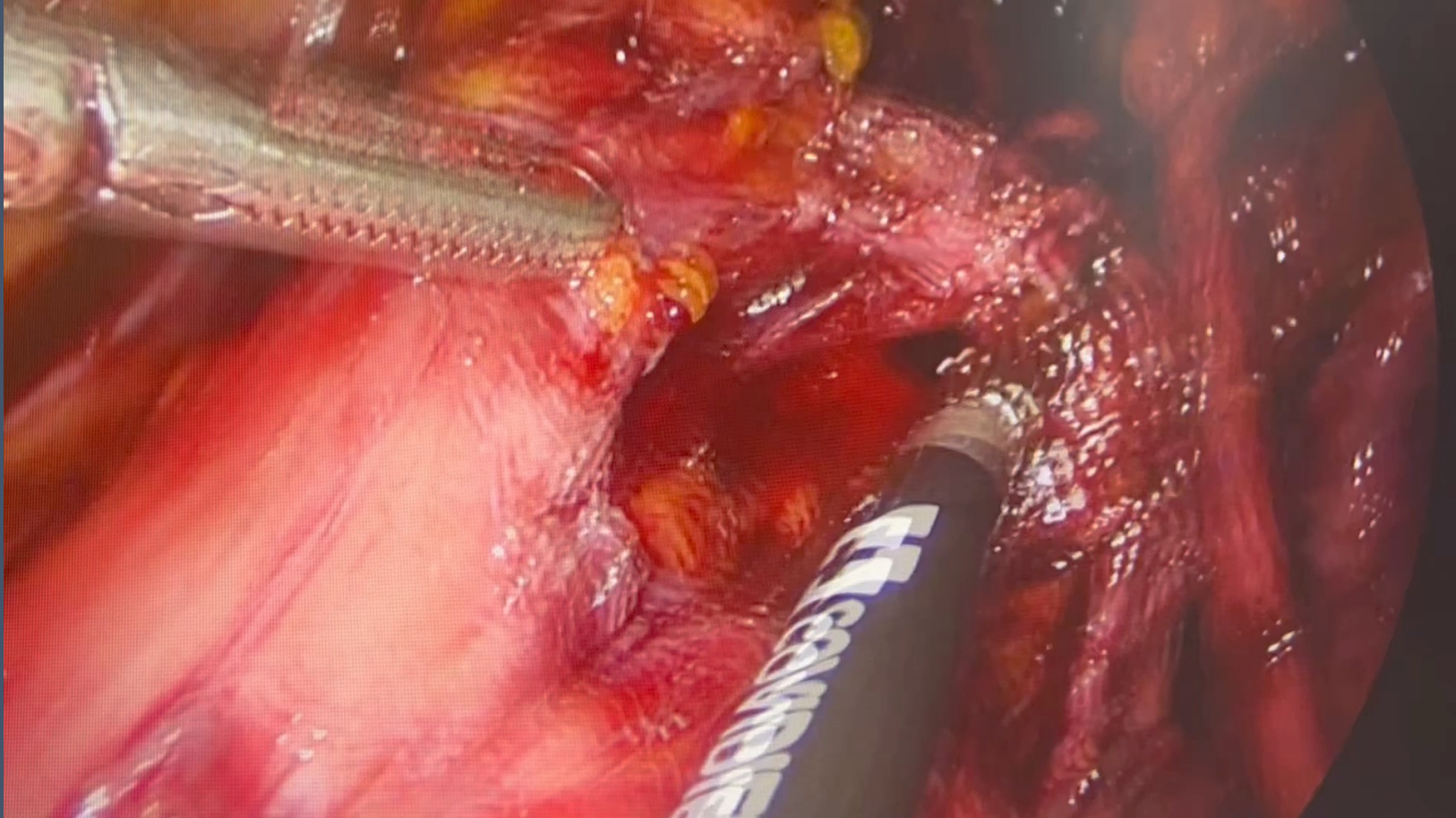


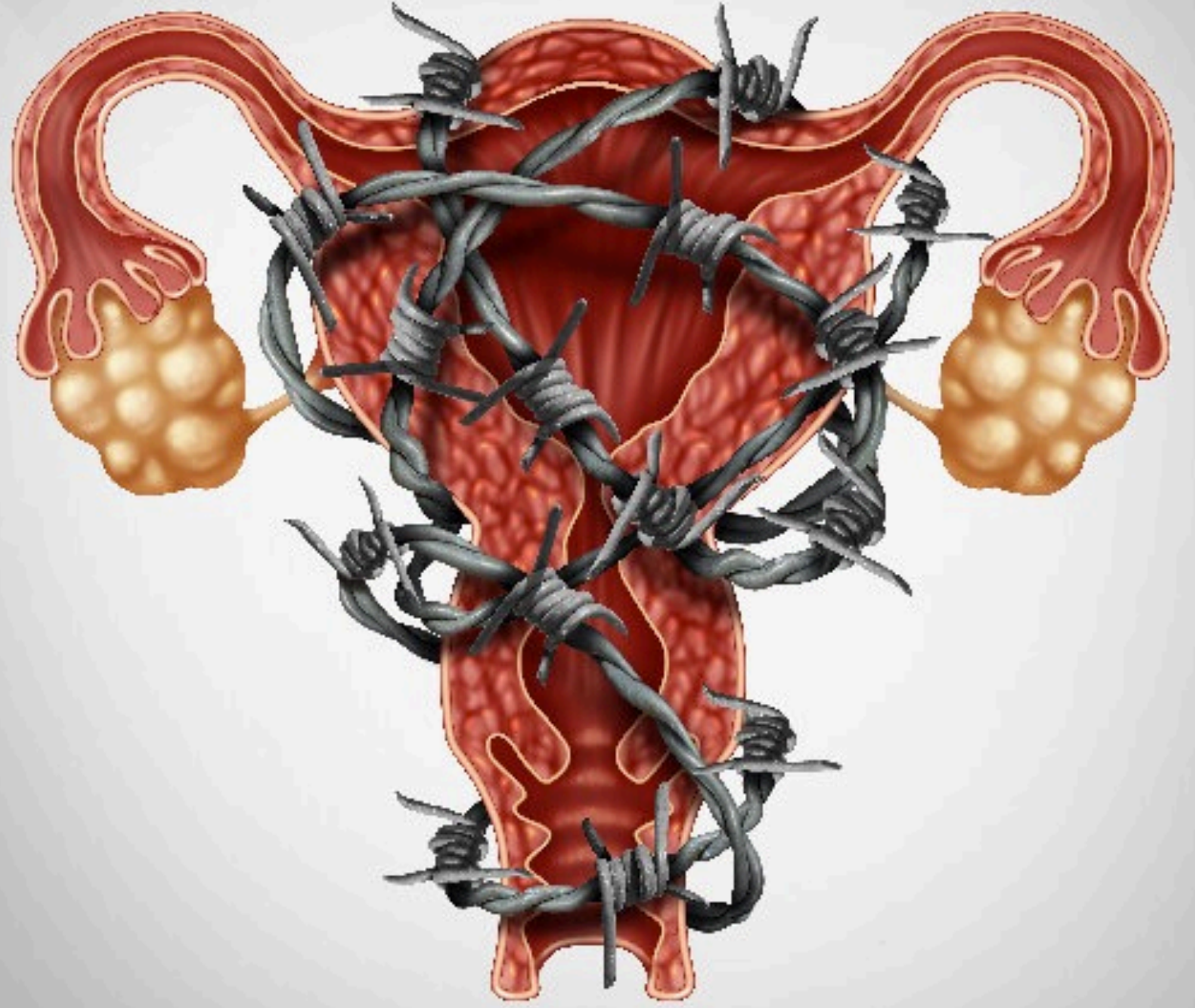


- SSF
- Epizyotomi komplikasyonları
- >4000 gr

- Proksimal tutulum?
 - Entrapment?









Bursa Uludağ Üniversitesi Kadın Hastalıkları ve Doğum Anabilim Dalı