



Genital Aesthetic Procedures

Doç.Dr. Özgüç Takmaz

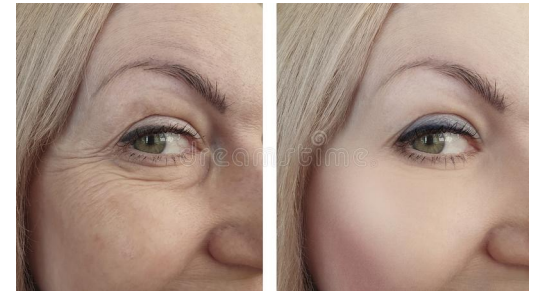Acibadem MAA Üniversitesi

Kadın Doğum Anabilim Dalı

Acibadem Maslak Hastanesi

Terminology

- Aesthetic: *esthétique* (Fr) “relating to beauty ”
- Cosmetic: *kosméō* (Gr) “ correcting, making for beauty especially ”
- Rejuvenation: restoration of youthful vigor, re-juvenile
- Functional!!



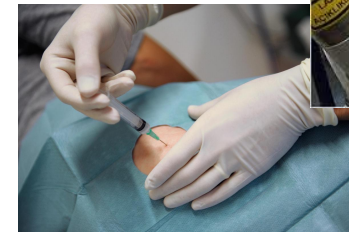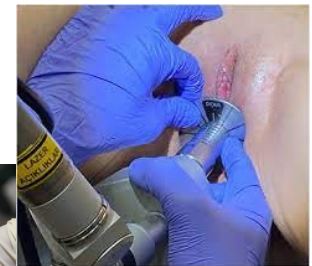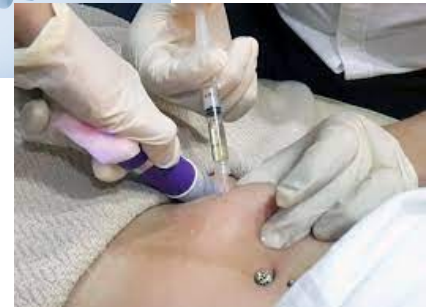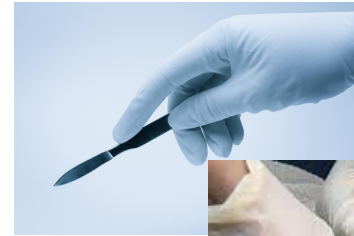Why?

- Internet/social media may drive women comparing themselves
- Aging
- 79% of women (2400, in US) had partially or totally removed their pubic hair, draw more attention to asymmetries and differences in the external genitalia
- Consumer marketing
- Physician tendency!!
- Increasing requests in US&Ca (migration) --- ACOG (2019)
- Demand of aesthetic vaginal procedures from 3.9% in 2012 to 28.97% in 2015



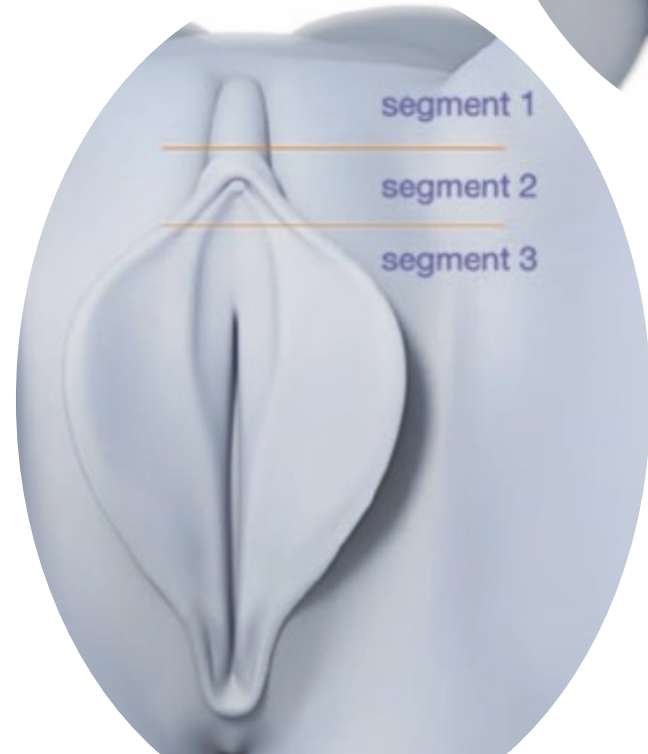
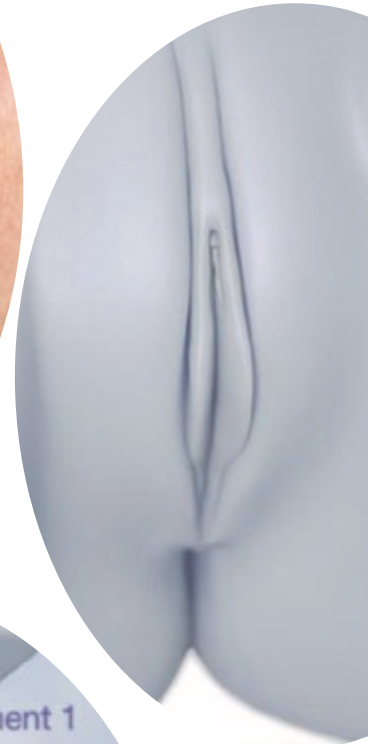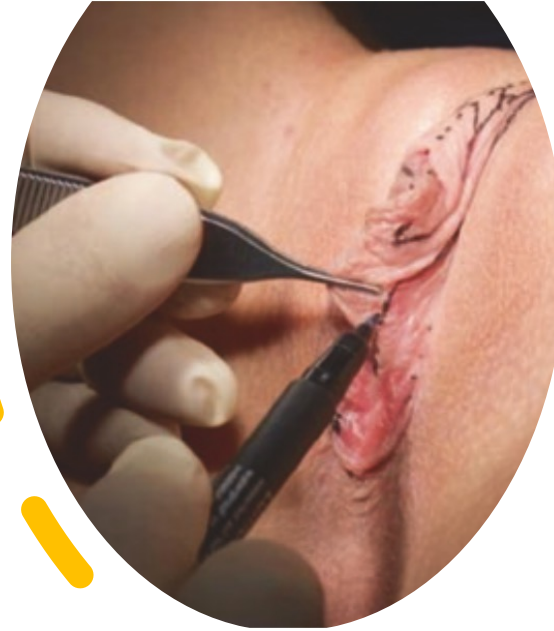
Genital Aesthetic Procedures

- Labioplasty
- Hoodoplasty
- Vaginoplasty / Vaginal Tightening
- Hymenoplasty
- Mons Pubis Reduction/ Lifting
- G-Spot amplification
- Genital Filling
- Genital Mesotherapy
- Genital Brightening / Whitening



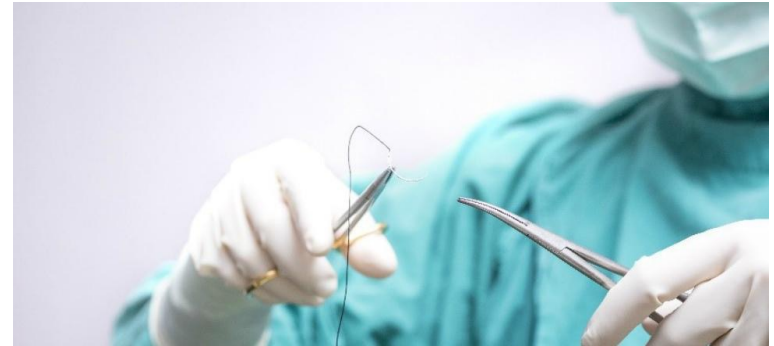Labioplasty

- Reduction of labia minora
- Indications??
- Segment 1-2-3 (acc. Clitoris)
- Markings before injection (midline , interlabial folds)
- Injection?? (10 ml 1% lidocaine with added adrenaline at a concentration of 1:100,000, 27-gauge)
- Local / General Anesthesia??



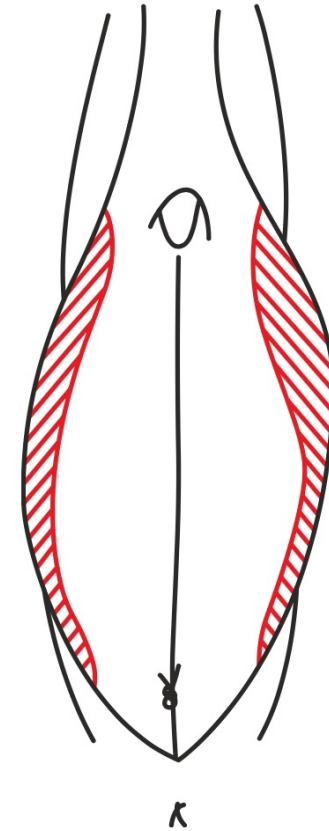
Labioplasty Techniques

- Linear Resection
- Wedge resection
- Composite reduction
- Central segment is removed
- Crescent-shaped segment resection
- Church spire resection
- Zig-zag excision
- Deepitalisation

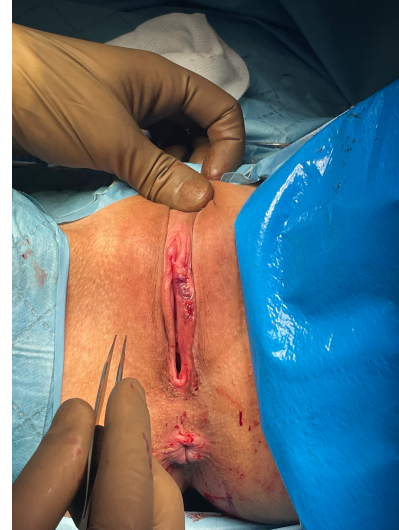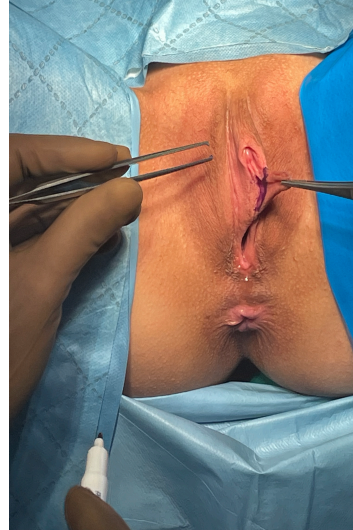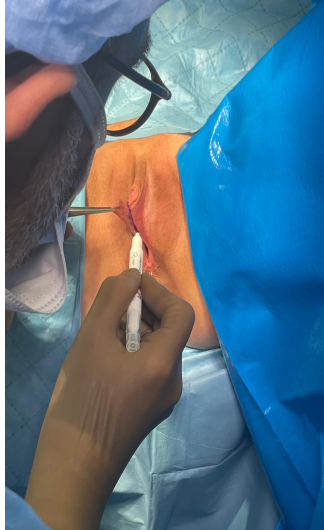
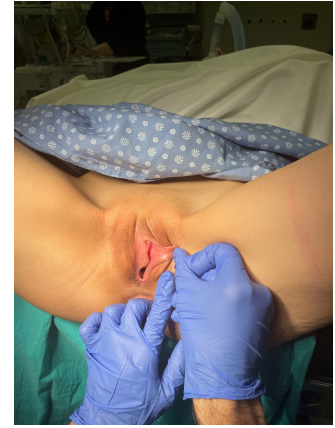


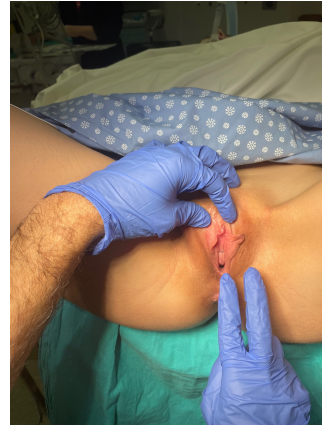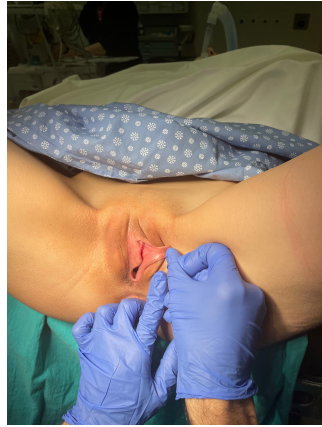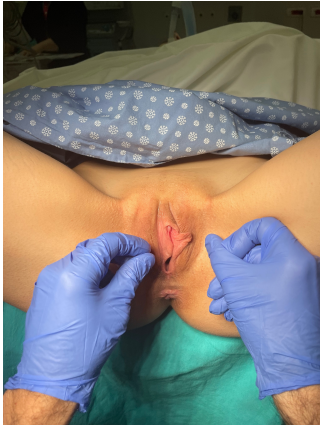Linear Resection

- D. J. Hodgkinson (Australia)
- Advantages: Symmetric
Depigmentation
Easy to perform
- Disadvantages: Contour defects (saw)
Edge sensitivity
Dog's Ear image
Segmental Discordance

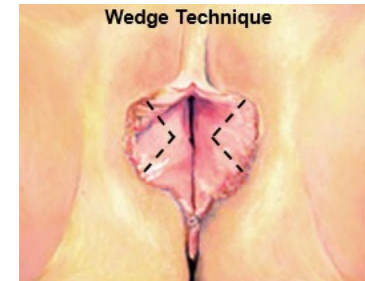
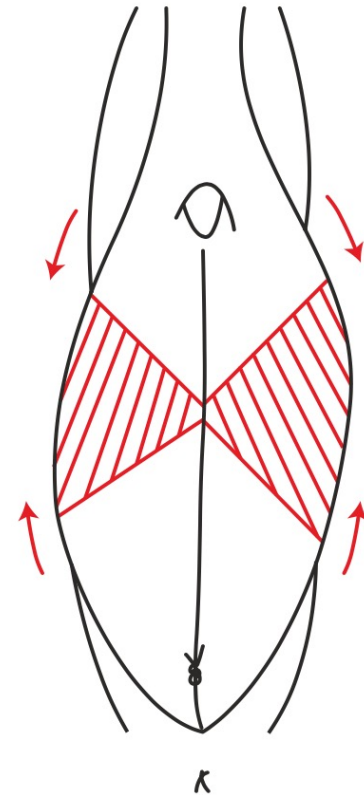


Lineer reseksiyon-2



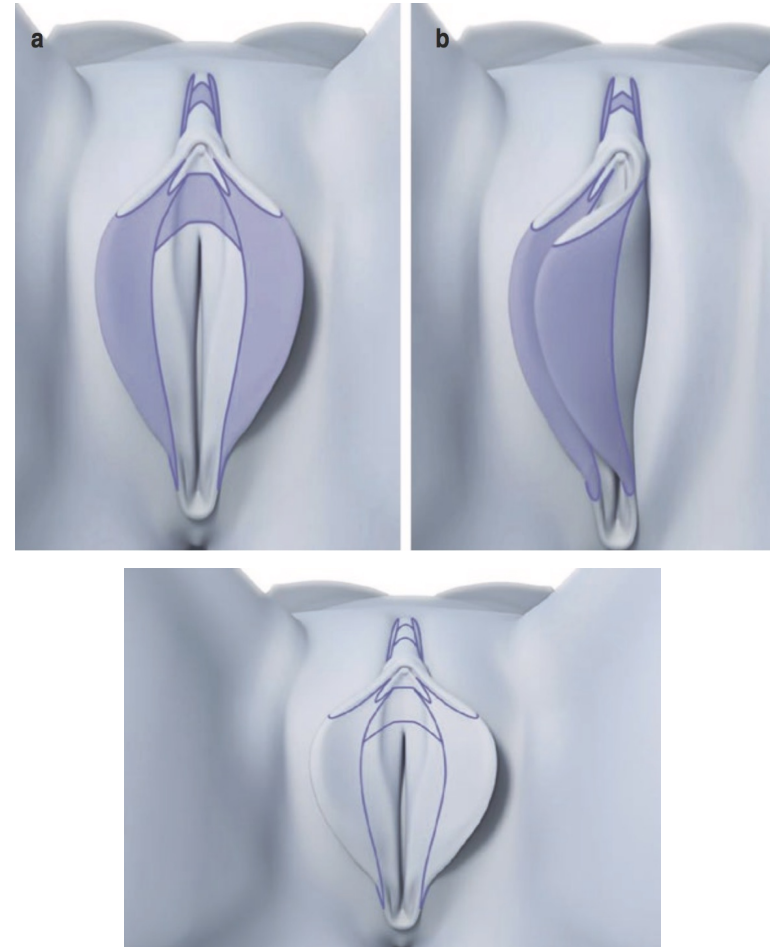
Wedge resection

- G. Alter, C. Trichot
- Resection of triangular section of the labium minora
- **Advantages:** Preserves natural edges
Hood can be reduced
Easy to perform
- **Disadvantages:** Dehiscence
Delayed Healing
Haematoma

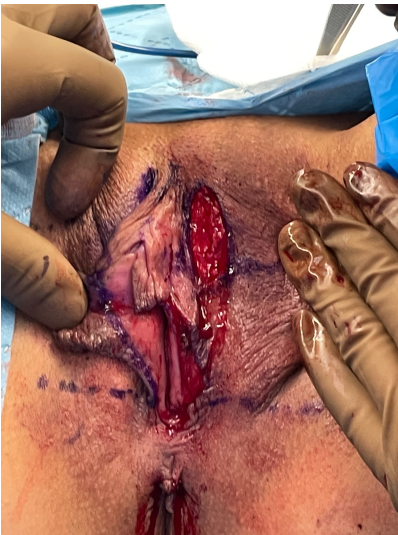
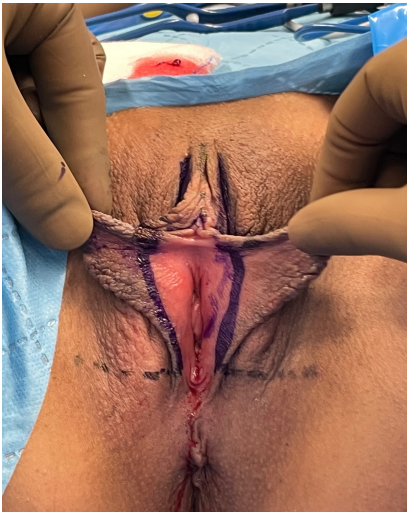
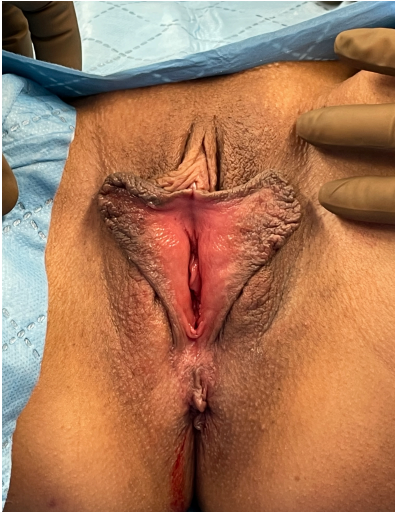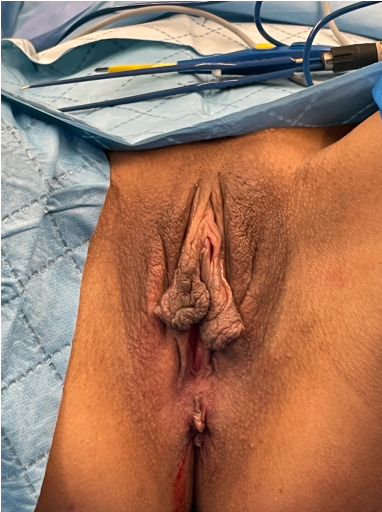Composite Reduction -1

- S.Grass
- Creates completely separate labial segments
- Suitable for hypertrophy of the labia minora in all three segments
- **Advantages:** Compose the vulva
Good healing
- **Disadvantages:** Hard to perform
Dehiscence
Hemmatoma

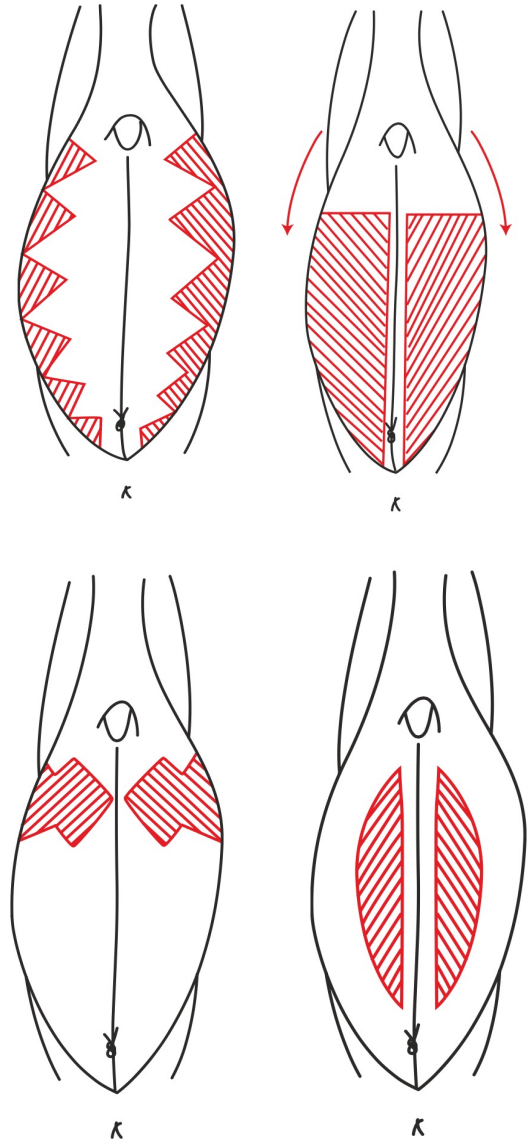


Composite reduction -2

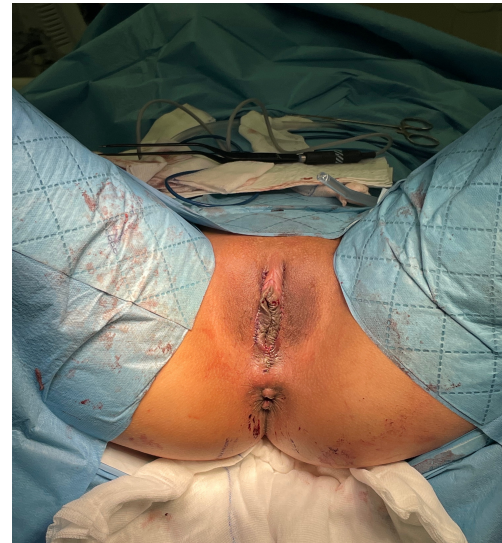
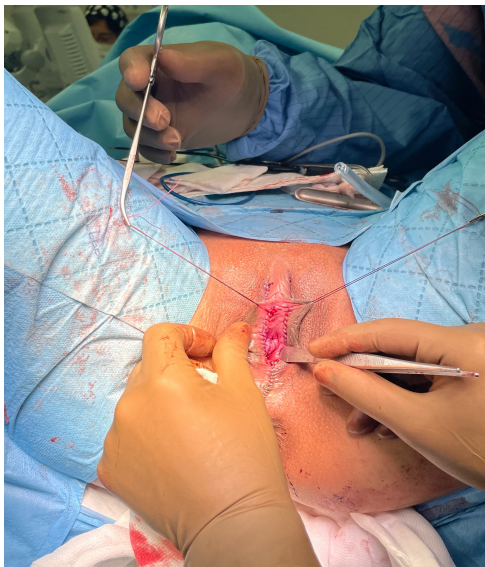
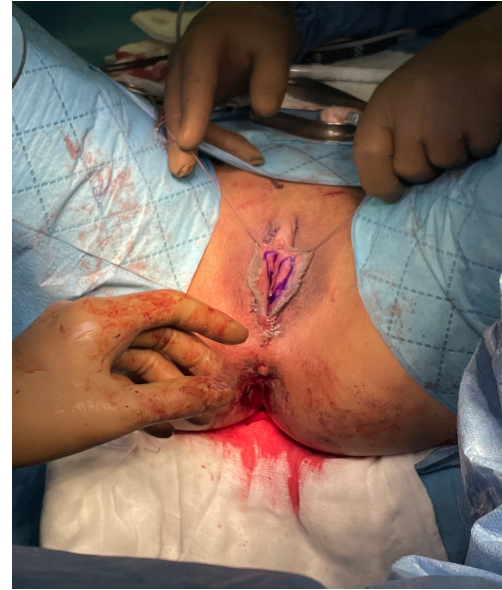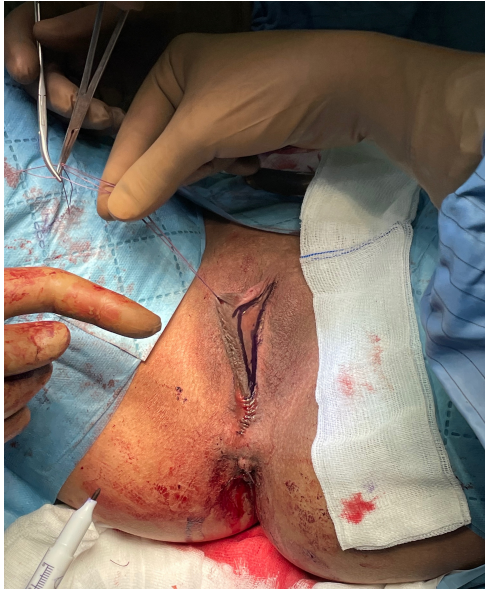Other Techniques

- Central segment is removed (**R. Rouzier**)
- Crescent-shaped segment resection (**H. Y. Choi**)
- Church spire resection (**F. Giraldo**)
- Zig-zag excision (**S. M. Maas**)
- Deepitalisation

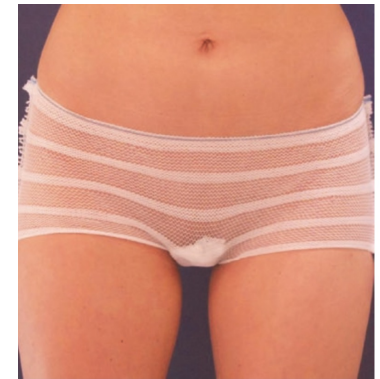

De-epitelisation



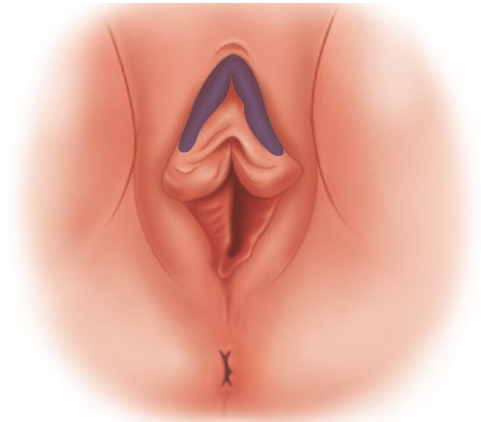
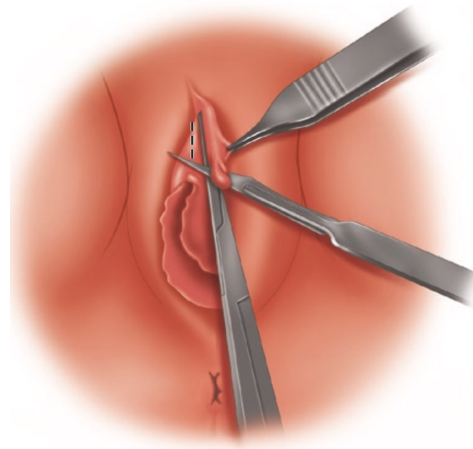
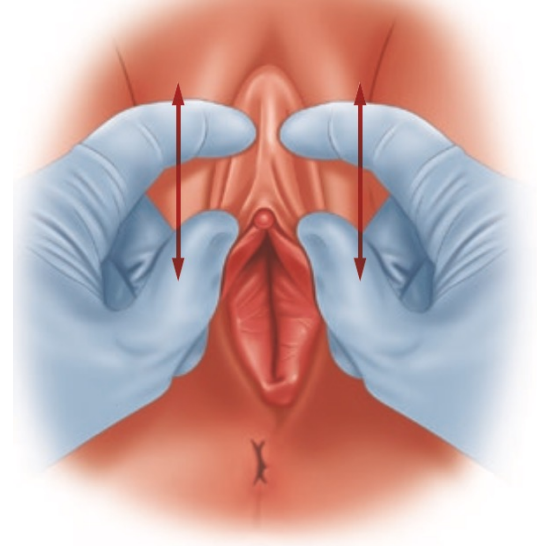
Post-operative

- Cool the genital area
- Wearing firm panties for one night
- Wear a gauze compress between the labia
- Showers are allowed after 2 days
- Cream / Intimate Wash??
- Excessive strain (intercourse, jogging, riding) should be avoided for 6 weeks



Hoodoplasty

- Describe the correction of excess skin on clitoris hood.
- cutting labia minora excess was not enough- «penis-like» preputium
- Lack of sensation and orgasm
- **Longitudinal Resection**
- **Horseshoe hoodoplasty**
- **Combined labia&hoodoplasty**

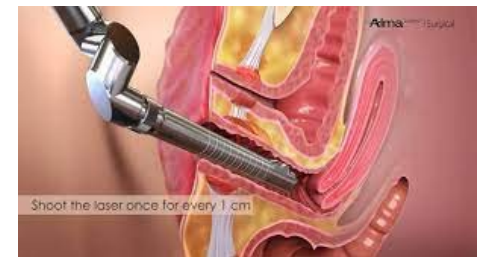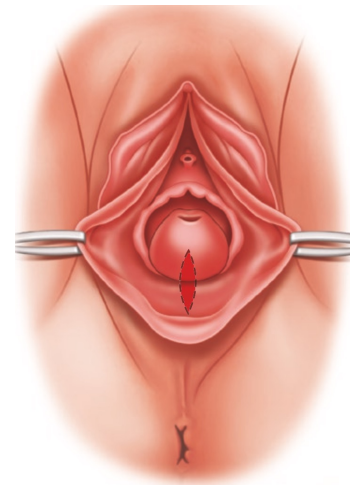
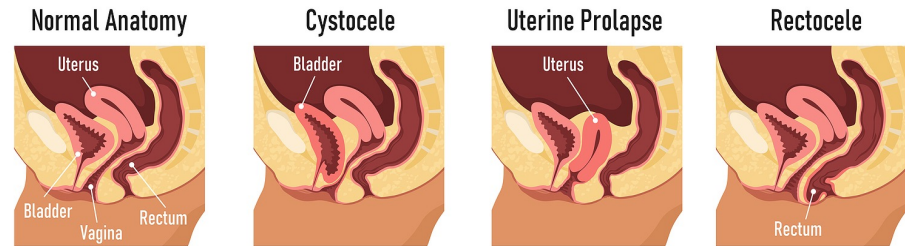


Vaginoplasty / Vaginal Tightening

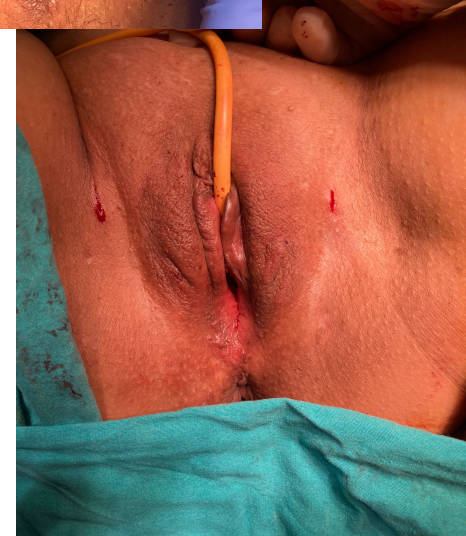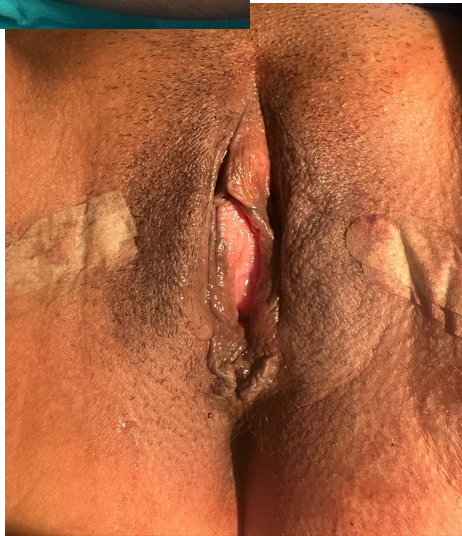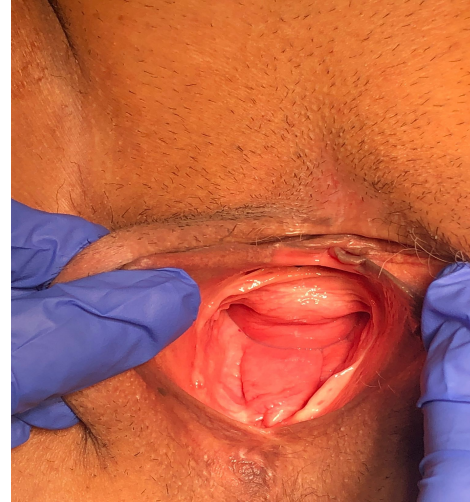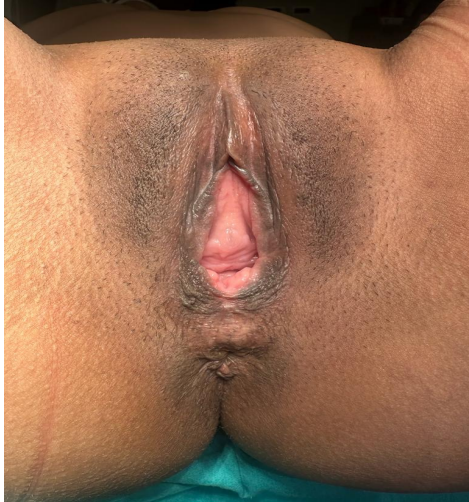(Rejuvenation)

- Colporaphy posterior and anterior
- Lasers
- *Radiofrequency Devices*
- *Fat Injections*
- Vaginal lifting
- Perineoplasty doesn't necessarily increase a female's sexual gratification.

TYPES OF PELVIC ORGAN PROLAPSE

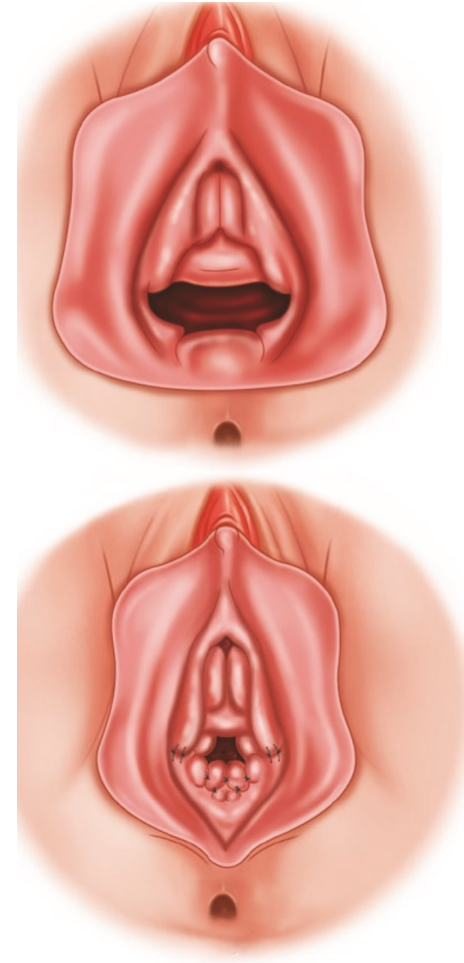


Vaginoplasty



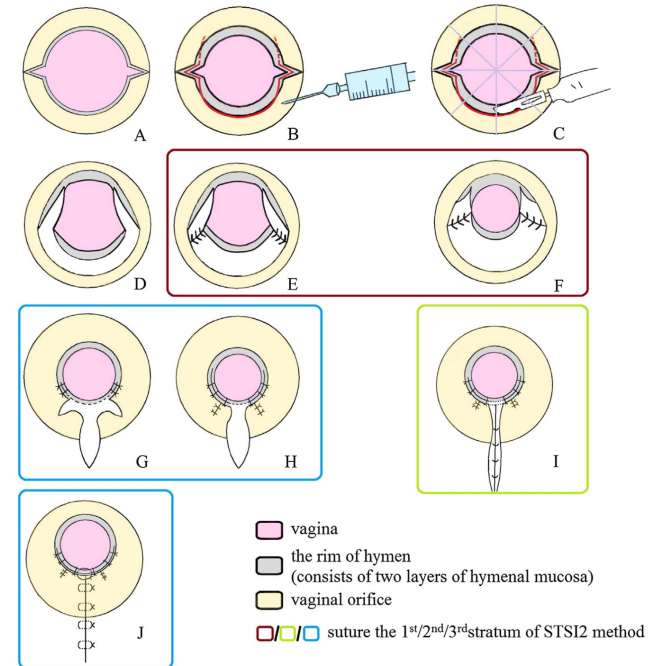
Hymenoplasty / Hymenorrhaphy / Revirgination-1

- **Controversial** (Religious, cultural, familial values)
- **Gender activists** oppose of **patriarchal** mindset
- %50 of **physicians reject** to perform in Be
- **RCOG call for ban virginity test and hymenoplasty (2021)**
- Letters to editors/ Comments to author!!
- **Increasing requests** in US&Ca (immigration)
- **Medicolegal issues!!!**

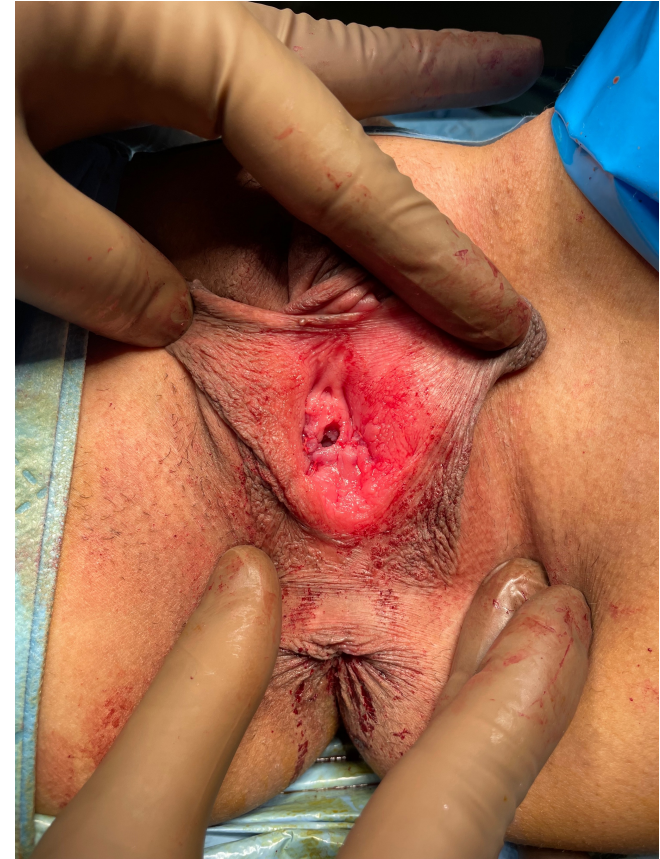
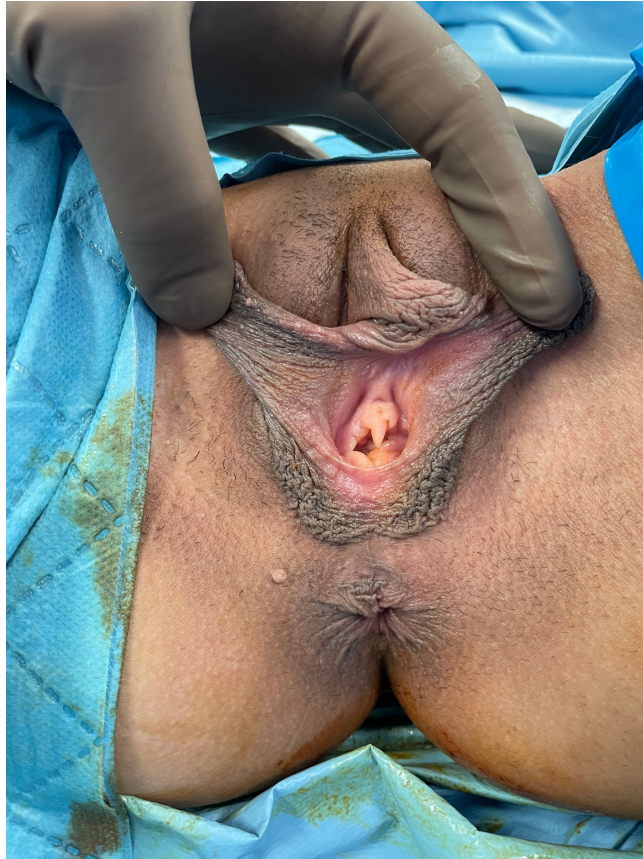
Hymenoplasty / Hymenorrrhaphy / Revirgination-2

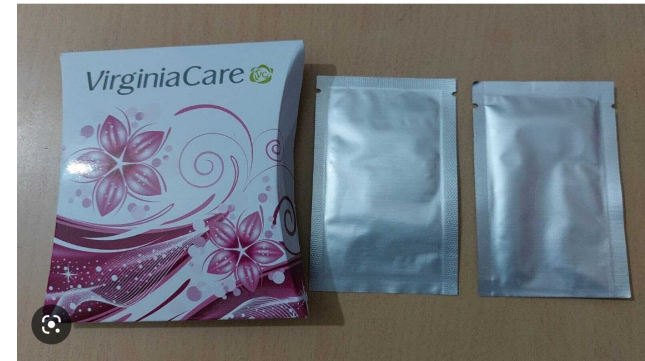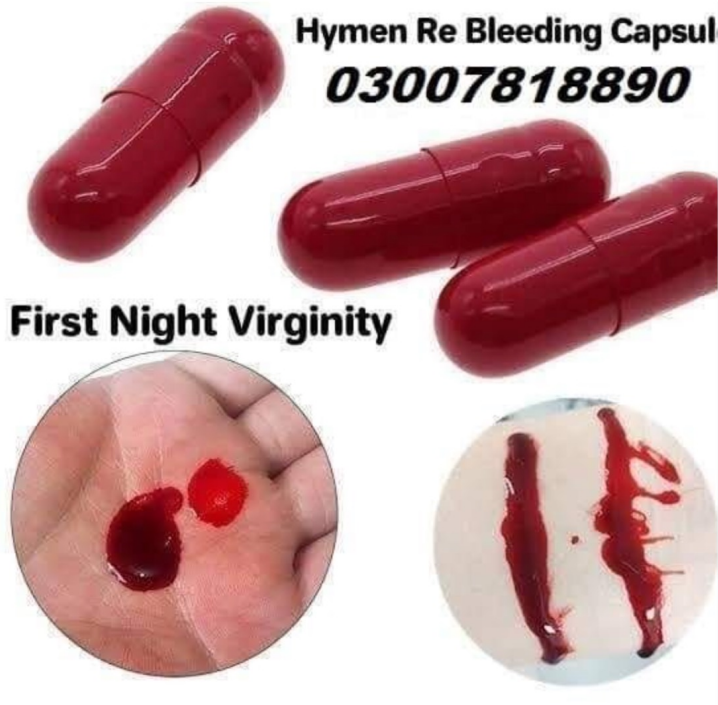- Enduring / Transient
- 2 Method: **approximation** and the **cerclage** method
- Diamond-shaped incision (Eserdag Tech)



Hymenoplasty / Hymenorrhaphy / Revirgination-3



Artificial Hymen (Virginity Capsules)



Virginia Care Artificial Hymen - Restore Virginity(2'S)

Git

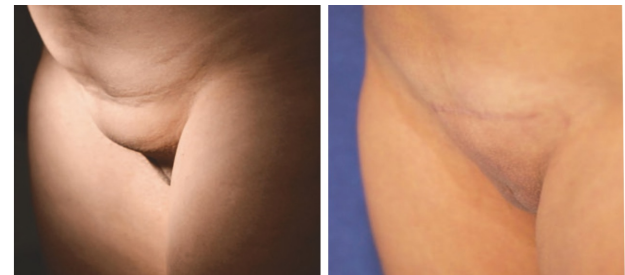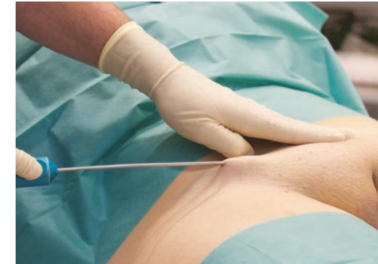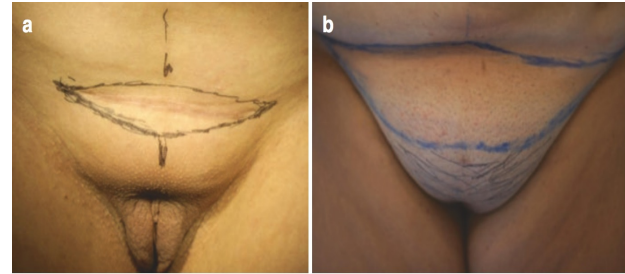
\$84,50 USD* · Stokta · Marka: Swayamacare Pvt Ltd



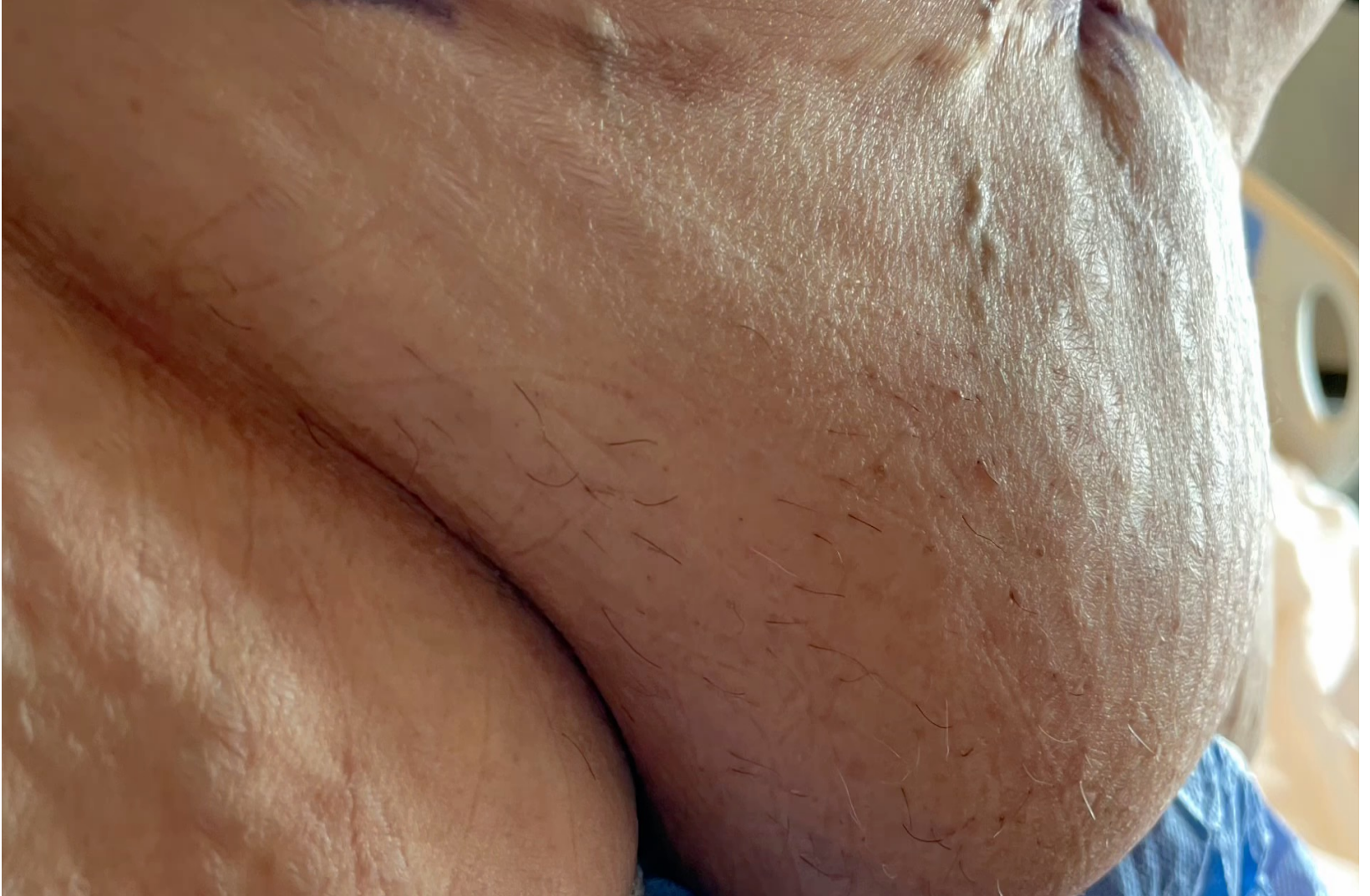ACIBADEM
MEHMET ALİ AYDINLAR
UNIVERSITY

Mons Pubis Reduction/ Lifting

- **Liposuction** (completes after about 6 months)
- **Tightening Up the Mons Pubis-** spindle-shaped excision of the suprapubic skin, at about the level of a Pfannenstiel incision



Monsplasty



ACIBADEM
MEHMET ALİ AYDINLAR
UNIVERSITY

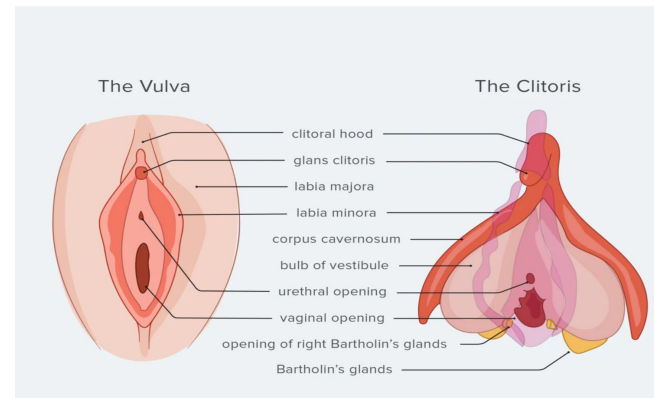
G-Spot amplification (G-Shot/O-Shot) -1

- Grafenberg spot
- Existence of the G-spot has not been proven
- **Vulvar Erogenous Zones!!**
- to increase the size, firmness, and sensitivity of the G-spot
- Injecting a filler composed of **collagen, hyaluronic acid, fat, PRP**
- «**Orgasm shot**» is injection of platelet rich plasma into clitoris, vagina, pubocervical fascia, and skene's glands.
- Neo-angiogenesis, fibroblast, and neuronal growth.



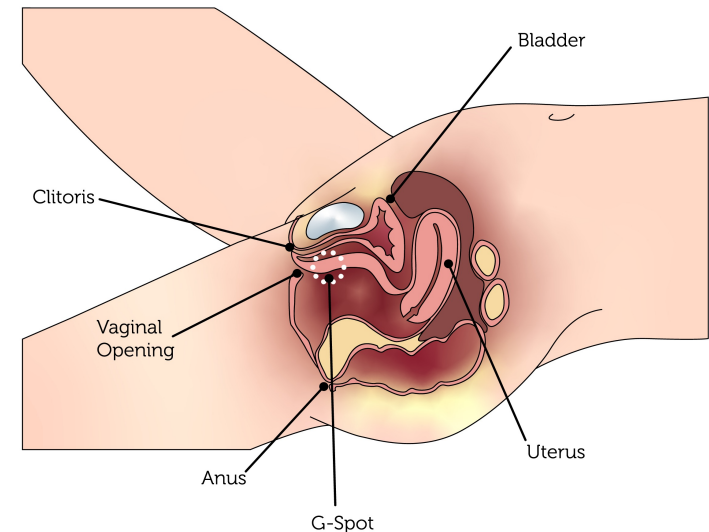
Hitting the G Spot: £800 injection to improve orgasms becomes LA's latest lunchtime craze | Daily Mail Online

Get



G-Shot -2

- Into a septum between the bladder and the front wall of the vagina, about **5 cm from the vaginal entrance**
- Hyaluronic acid
- Fat injection (Lipofilling)
- PRP
- PRP + HA
- **lack of data** regarding a role of these products for enhancing sexual function



This part of the vagina has the highest concentration of nerves. Direct stimulation helps to achieve orgasm. This is often referred to as the G-Spot

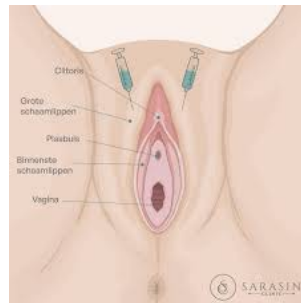


Genital Filling



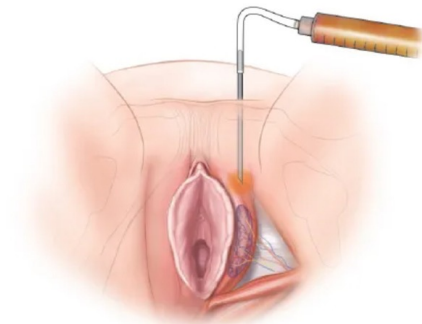
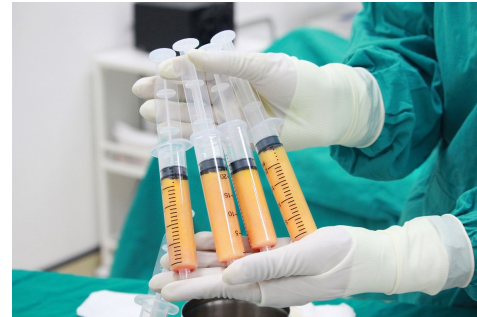Hyaluronic Acid

- Available as prefilled syringes
- Injected into the deep dermis
- must be repeated every 6 to 12
- injections to labial border
- **is not FDA approved** for vaginal use
- **ACOG does not endorse it as effective or safe**



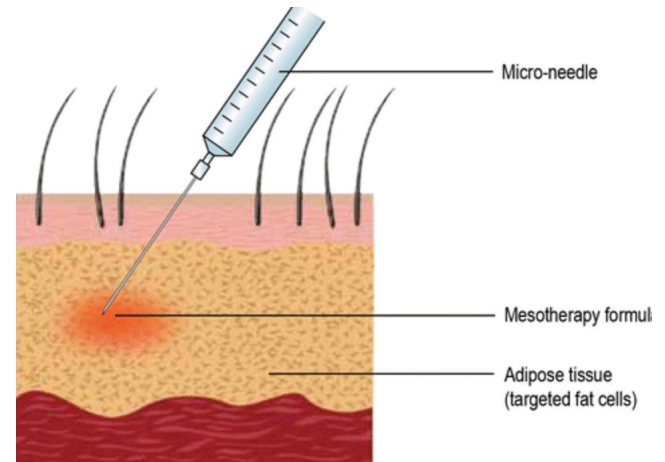
Fat Injections

- massive weight loss
- harvested by liposuction



Genital Mesotherapy

- Mesotherapy microinjections of pharmaceuticals, vitamins, enzymes, proteins, etc. are delivered into the **mesodermal** layer of skin
- Stimulates subcutaneous collagen and elastine fibers. Rejuvenate and tighten the skin, remove excess fat
- **Indications:** Genital rejuvenation, bleaching, lipolysis, stria-scar treatment
- **Ingredients:** phosphatidylcholine (PC), L-carnitine, aminophylline, hyaluronidase, collagenase, glycolic acid, retinoic acid, **multivitamins** (A, D, E, K), trace elements [minute quantities of **zinc, copper, selenium, chromium** and **manganese**], an acetylcholine analog dimethylaminoethanol (DMAE), **hyaluronic acid, salmon DNA, tranescamic acid, glutation, lidocaine** etc.
- growth of number of mesotherapy-trained physicians by 300 per month
- **Tecnique:** 30G, 4-6-13mm needles (**3-6mm**), **Once in 10 days for 1 month, repeat at 6 months later**



Product Name	Mesotherapy needle/Disposable Needle
Application	Injection needle
OEM	Support OEM
Needle Size	30G, 31G, 32G, 34G
Needle Length	4mm, 12mm, 13mm, 25mm
Needle Type	Sharp Needle

Use anesthetic

Screw adjustable/ Play above 4mm

Use of water light needle 4mm

Best soluble fat and botulinum toxin 13mm

25mm



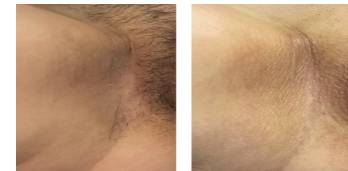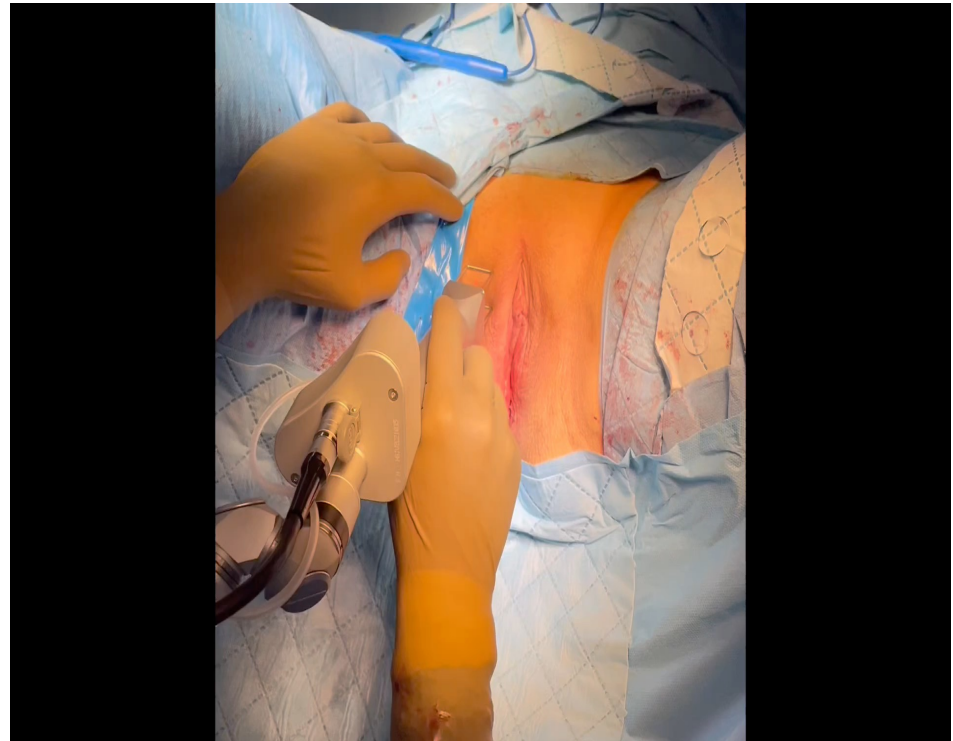Mesogun MesoP1 Mesotherapy Gun Purchase Site
France, Switzerland, Monaco
CHF 2.990,00* - 00000



ACIBADEM
MEHMET ALİ AYDINLAR
UNIVERSITY

Genital Brightening / Whitening

- **Mesotherapy & Laser**
- **Mesotherapy:**
Tranescamic acid +
Glutathione and vitamins
- Superficial
- 30G needle
- 3 times in a month with
10 days interval



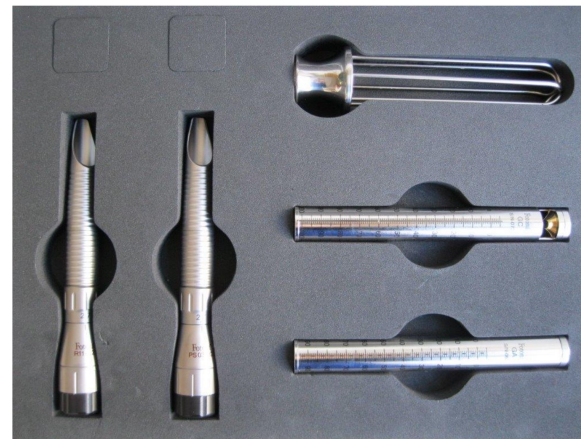Genital Laser Procedures

Gynecology

- Urinary incontinence (Stress, Mixed)
- Cystocele, rectocele
- Genito-urinary syndrome of menopause
- Condyloma
- Cervical lesions
- Recurrent vaginal infections
- Vulvodynia
- Lichen sclerosis

Genital Aesthetic/Cosmetic

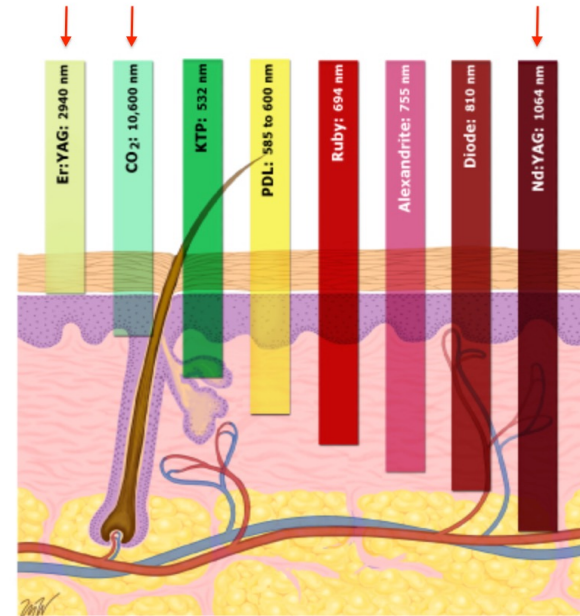
- Vaginal tightening
- Vulvar bleaching
- Episiotomy and c-section scar revisions
- Labiaplasty
- Vaginal rejuvenation



LASER (Light Amplification by Stimulated Emission of Radiation)

- **Gas** : Helium, Argon, Nitrogen, **Co₂**, CO
- **Chemical**: HydrogenFlouride, Coil
- **Solid-State**: **Nd:YAG**, **Er:YAG**
- **Semi-conduct**: Diode

Laser penetration into skin

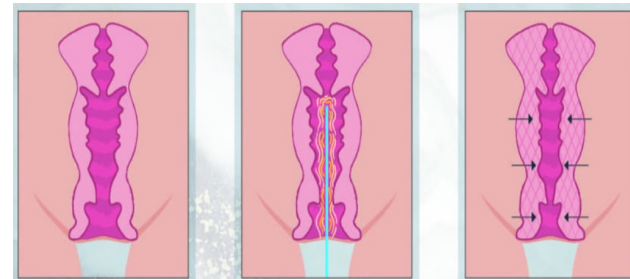
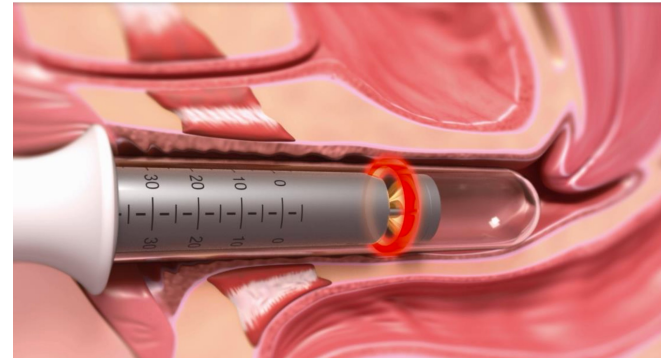


In the range of visible light and near infrared light (400 to 1200 nm), lasers that emit long wavelengths of light penetrate more deeply into the skin than lasers that emit shorter wavelengths of light. Mid-infrared (eg, Er:YAG) and far-infrared (eg, CO₂) lasers do not follow this rule. Heavy absorption by water in the skin greatly limits the penetration of these lasers.



Lasers in Aesthetic Gyn

- **Co2:** Superficial, Ablative effect, skin damage?
- **Er:Yag:** Non-Ablative, deeper effect
- **Nd:Yag:** Deeper, vascular effect
- Superiority??
- Effectivity???



DOI: 10.1111/j.1471-0528.12.3213.x

RESEARCH ARTICLE

Laser versus sham for genitourinary syndrome of menopause: A randomised controlled trial

Ann-Sophie Page¹ | Jan Y. Verhaak^{2,3} | Joha Verheghe⁴ | Yani P. Latal⁵ | Susanne Houmann⁶ | Jan Deprest⁷

Abstract Objective To assess whether CO₂ laser treatment is more effective than sham application in relieving the most bothersome symptoms (MBS) in women with genitourinary syndrome of menopause (GSM). Design Single-centre, sham-controlled, double-blind, randomised trial, setting A tertiary centre in Belgium. Population Postmenopausal women with moderate to severe GSM symptoms. Intervention CO₂ laser treatment (1000 pulses) versus sham laser and three consecutive sham applications, either first laser followed by sham, or control. Main outcome measures The primary outcome was the percentage reported change in severity of the MBS at 12 weeks. Secondary outcomes included subjective patient satisfaction, sexual function, urinary function and objective pH, vaginal health index score, in vivo microscopy measurements assessing the short-term effect and the longevity of treatment effect at 48 weeks after start of the therapy. Adverse events were reported at every visit. Results The MBS severity score decreased from 2.86±0.33 to 2.27±0.51 (-23.69%; 95% CI -36.39 to -11.09) in women treated with laser compared with 2.92±0.33 to 2.52±0.78 (-13.29%; 95% CI -22.70 to -3.79) in those receiving sham applications (P=0.02). There were no serious adverse events reported up to 48 weeks. Conclusions In women with GSM, the treatment response 12 weeks after laser application was comparable to that of sham application. There were no obvious differences for secondary outcomes and no serious adverse events were reported.

KEYWORDS genitourinary syndrome of menopause, randomised controlled trial, vaginal laser therapy



Society

- **International Society of Cosmetogynecology- ISCG**
- **European Society of Aesthetic Gynecology- ESAG**
- **American Aesthetic Association- AMERIAA**
- **European Association for Genital Aesthetic Medicine and Plastic Surgery- EAGAMPS**
- **International Training Center of Genital Aesthetic- ITCGA**
- **International Society of Aesthetic Genital Surgery and Sexology- ISAGSS**





ozguc.takmaz@acibadem.com



ACIBADEM
MEHMET ALİ AYDINLAR
UNIVERSITY