



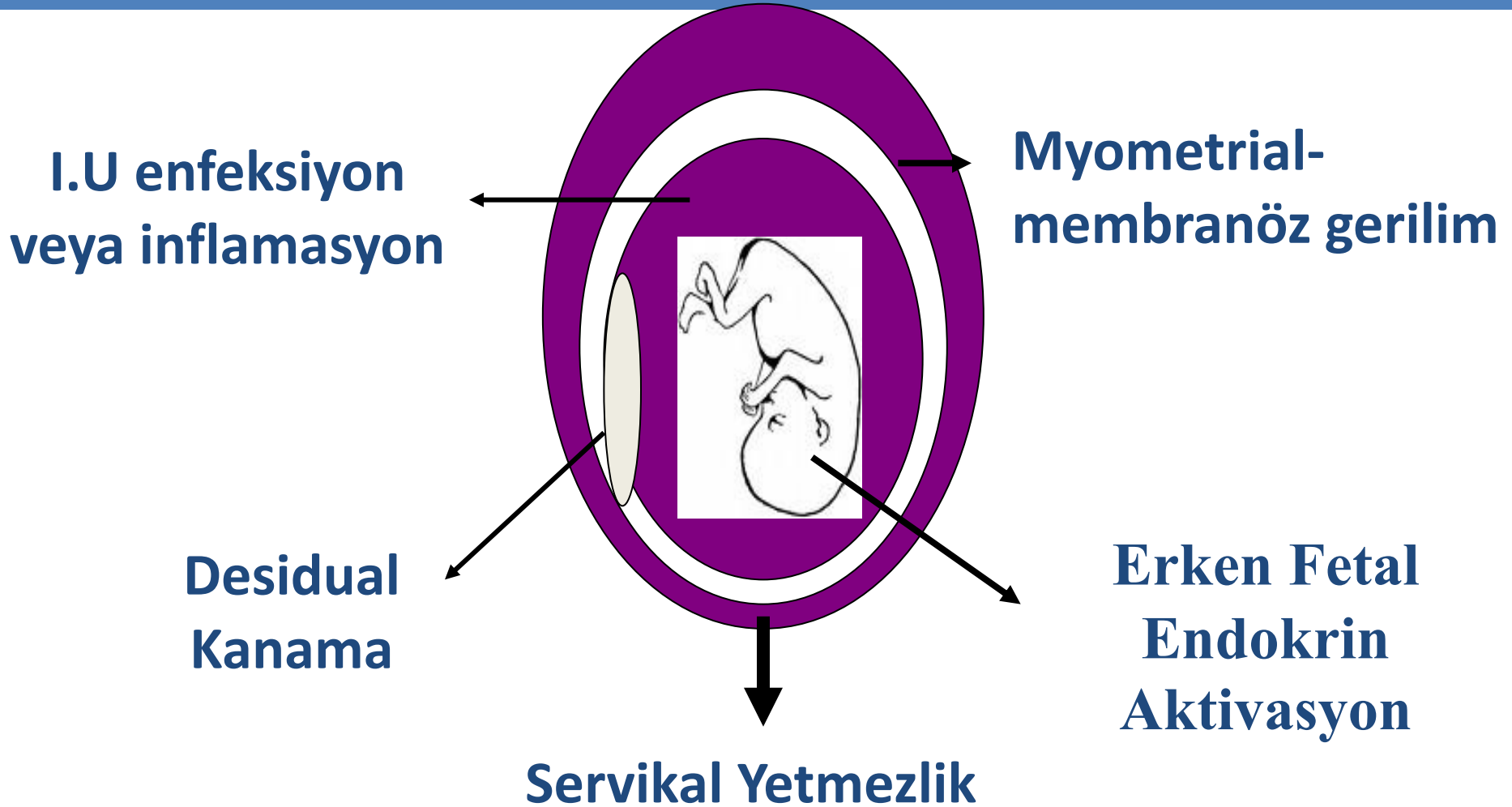
ACIBADEM
ÜNİVERSİTESİ
TIP FAKÜLTESİ



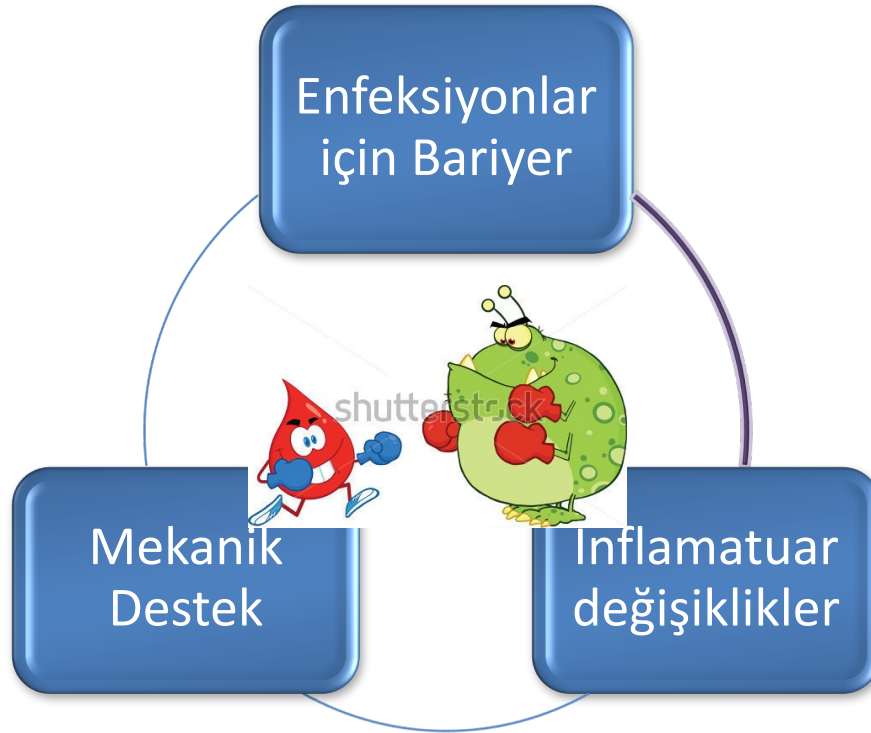
Gebelikte Minimal İnvazif Serklaj Özlem Pata

Acıbadem Üniversitesi Tıp Fakültesi Kadın Hastalıkları ve
Doğum A.D, Perinatoloji Bilim Dalı Başkanı

Spontan Preterm Eylem ve PPROM Heterojen Sendrom



Preterm Eylem Serviksin Rolü



TERM

PRETERM

Servikal Yetmezlik

Tanı

- ∞ Ağrısız servikal dilatasyona ikincil tekrarlayan ikinci veya erken 3. trimester gebelik kaybı öyküsü.
- ∞ Minimal uterin aktiviteye rağmen membranların prolabe veya rüptüre olması

Tanı

Tekrarlayan ağrısız ikinci trimester gebelik kaybına yol açan servikal dilatasyon.

ACOG 2014
Bergella V. Cervical insufficiency. **UpToDate**
2023

Spesifik bir tanı kriteri yok

Servical Serklaj

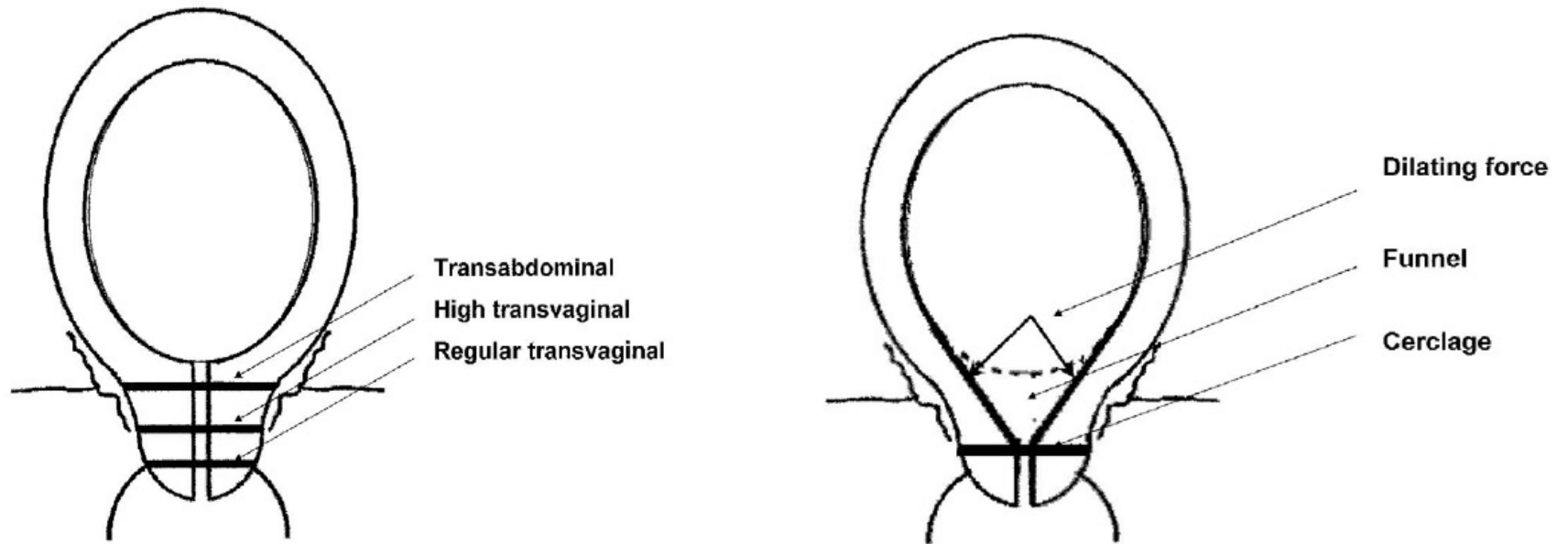


Figure 1
Three types of cerclage.

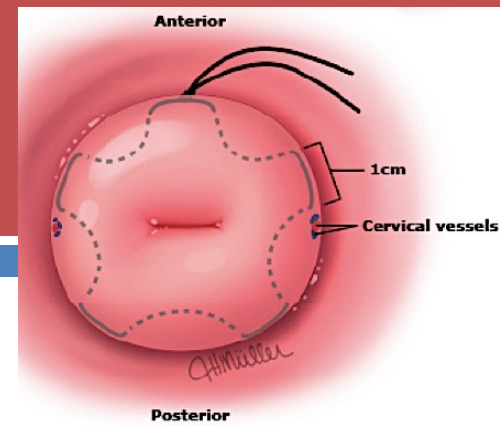
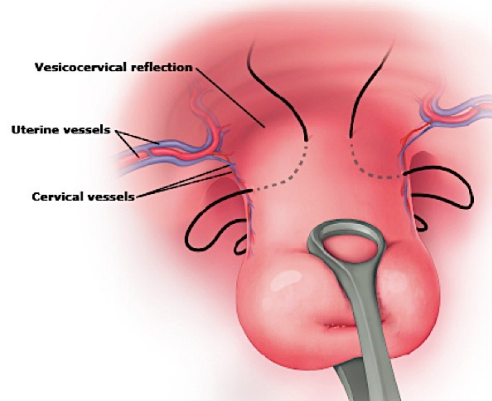
Figure 2
Funnelling.



Figure 3
Three types of suturing.

Serklaj

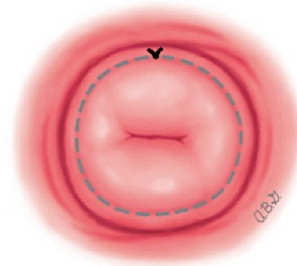
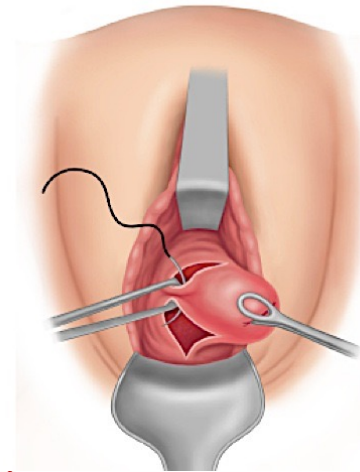
McDonald cerclage



Shirodkar cerclage

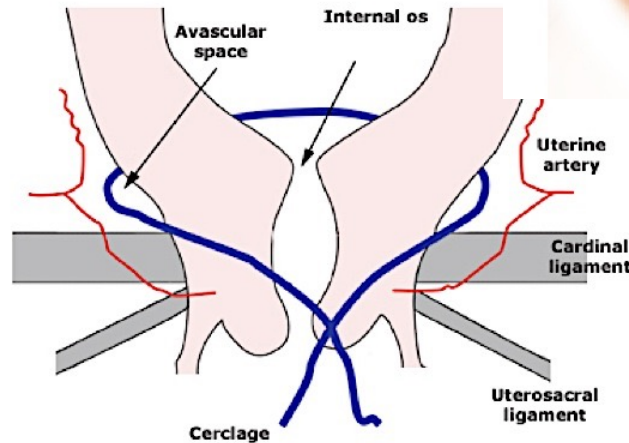
Vaginal
cerclage

- McDonald
- Shirodkar

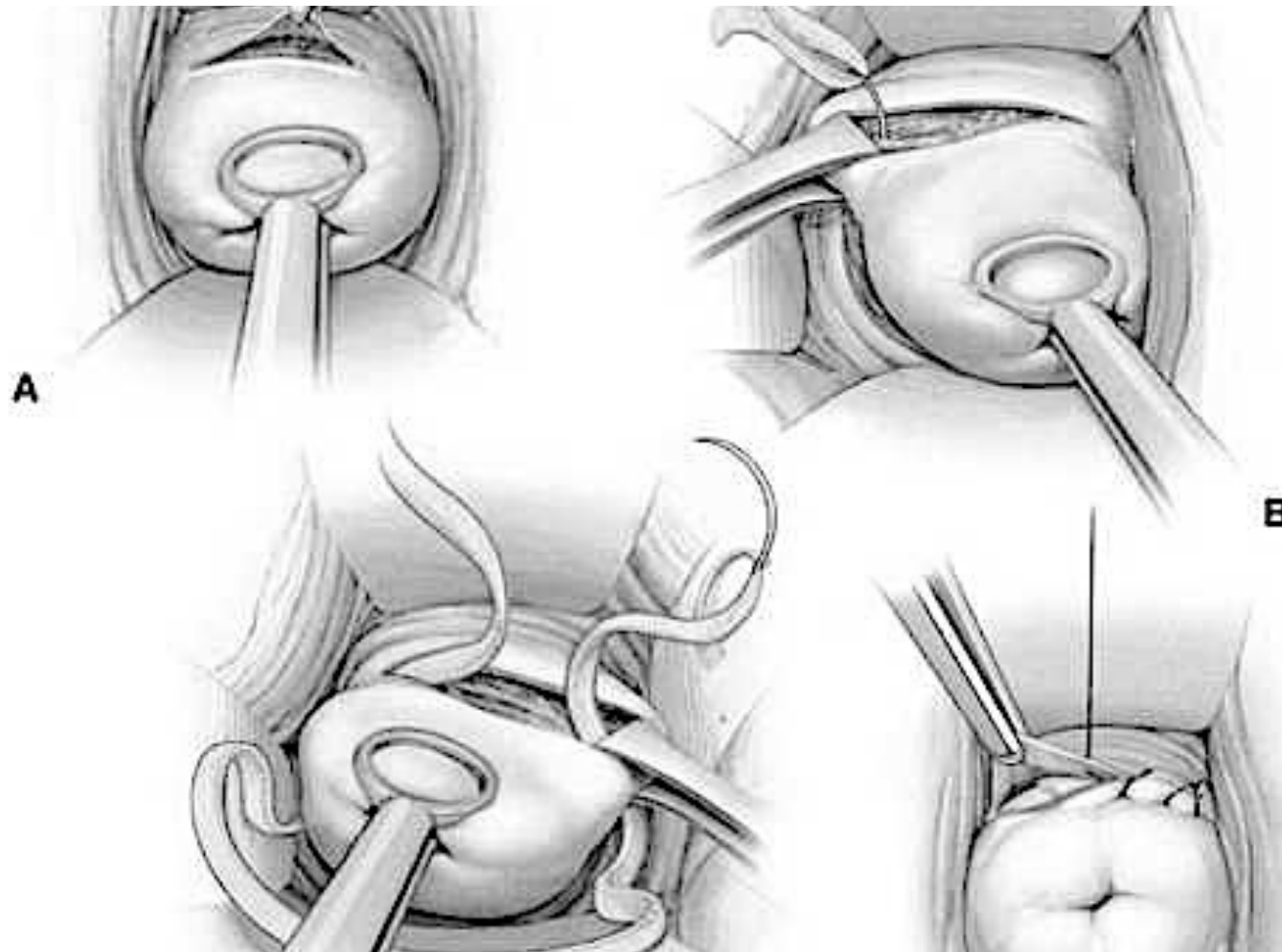


Transabdominal cerclage

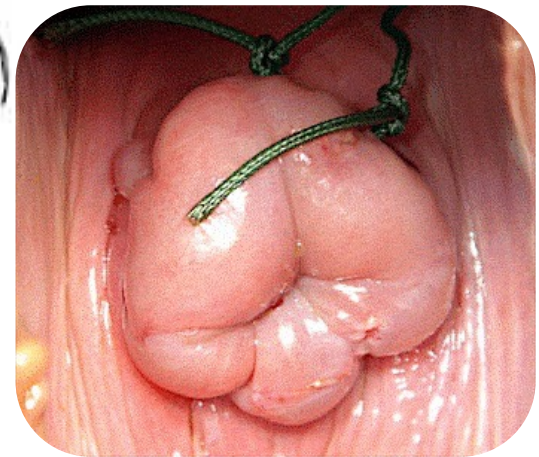
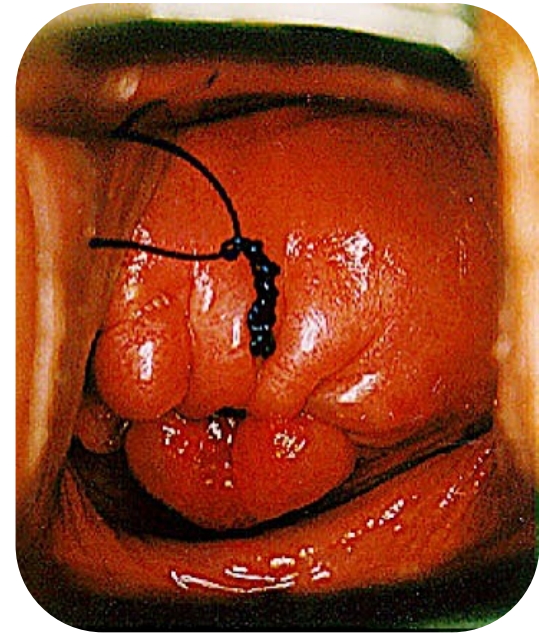
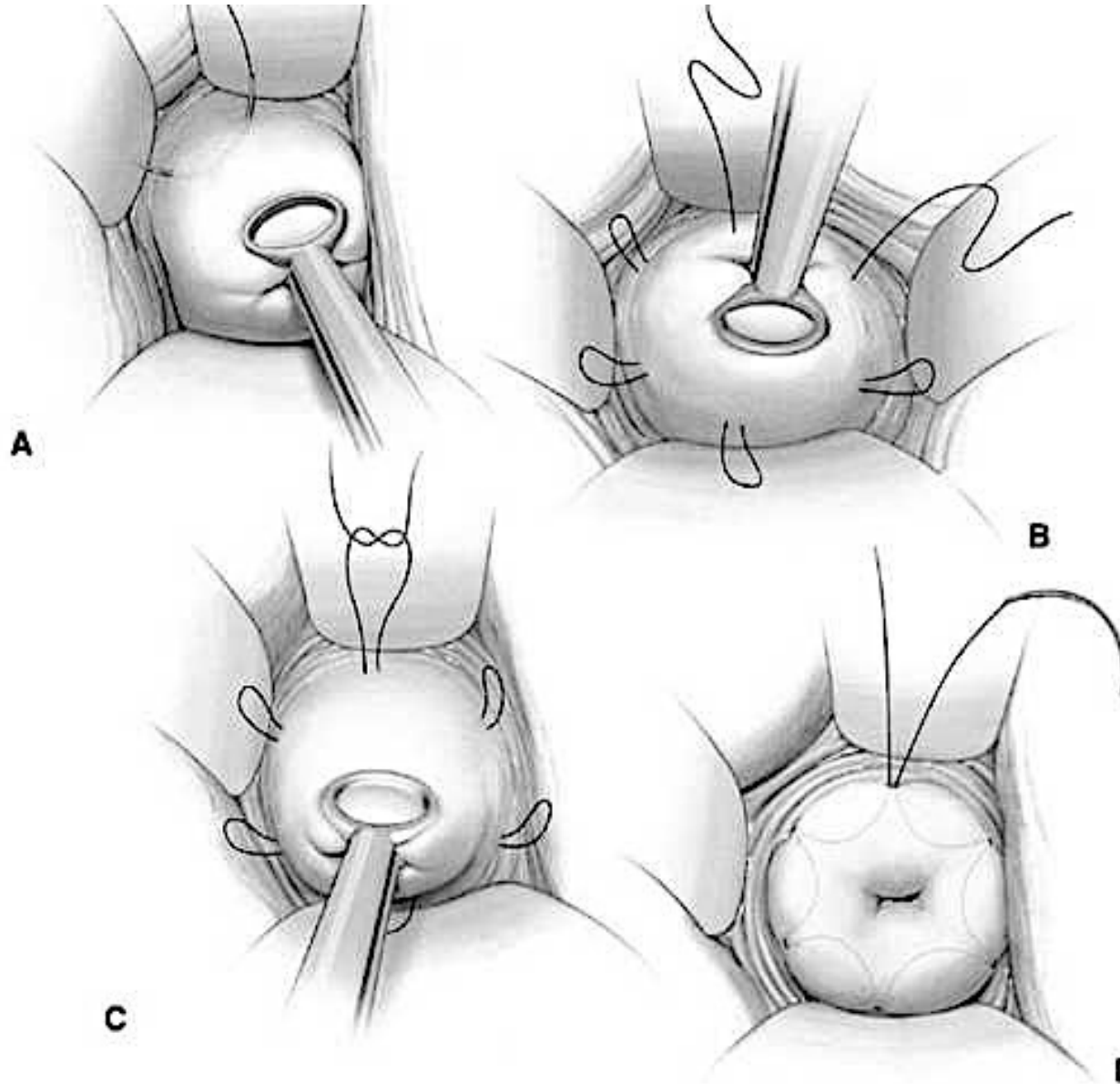
Abdominal
cerclage



Modified Shirodkar



McDonald



Servikal serklajın amacı serviksin mekanik kuvvetini arttırmak böylece ağrısız pasif

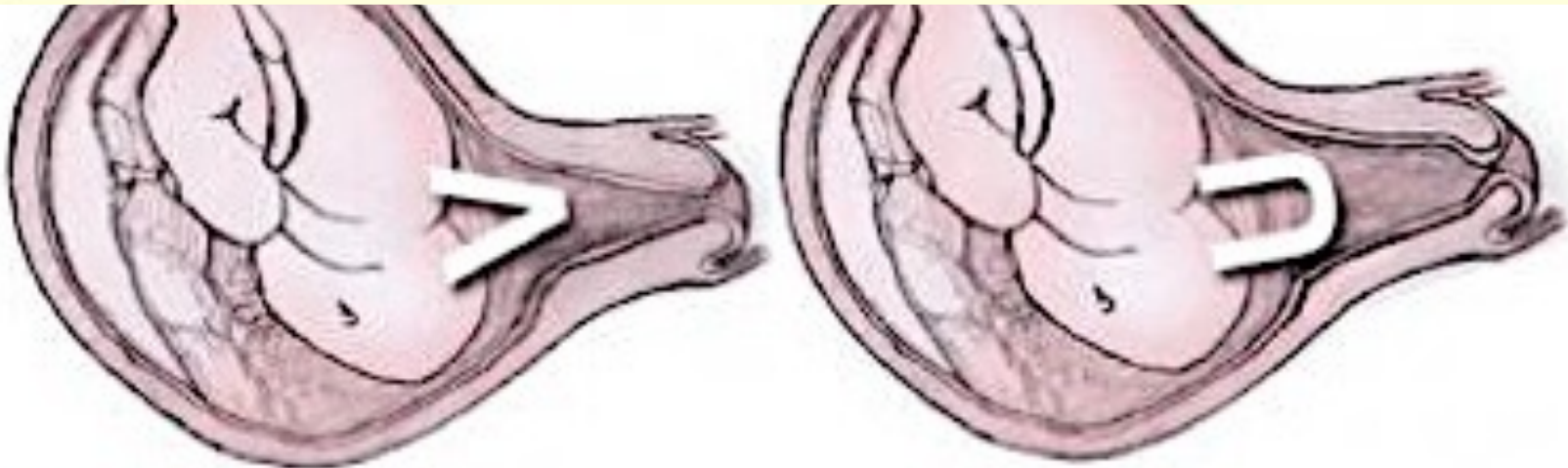

Cervical Cerclage

- Author: Allahyar Jazayeri, MD, PhD, FACOG, DACOG, FSMFM; Chief Editor: Ronald M Ramus, MD more...

Updated: Dec 22, 2015

Technique



Stages of incompetent cervix.

Kime Serklaj?

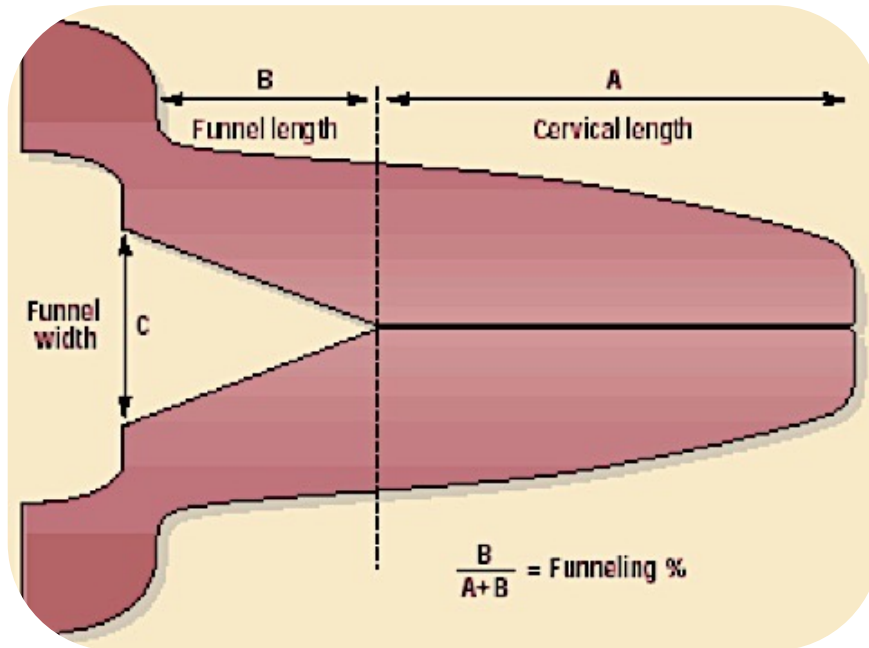
☞ Öyküye dayalı (Elektif)

- Transvaginal
- Transabdominal

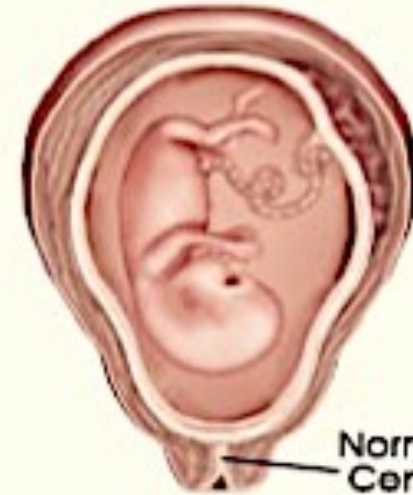☞ Ultrason Endike

☞ Kurtarma Serklajı

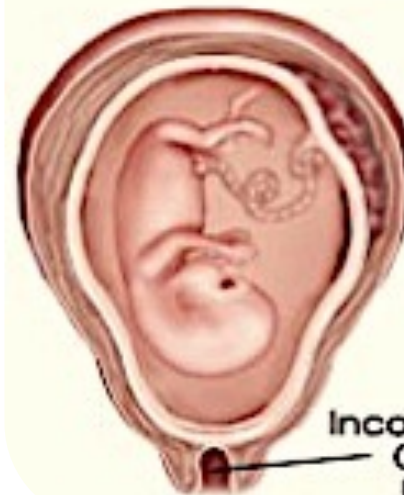Yetersiz Serviks - Servikal Yetmezlik



Incompetent Cervix

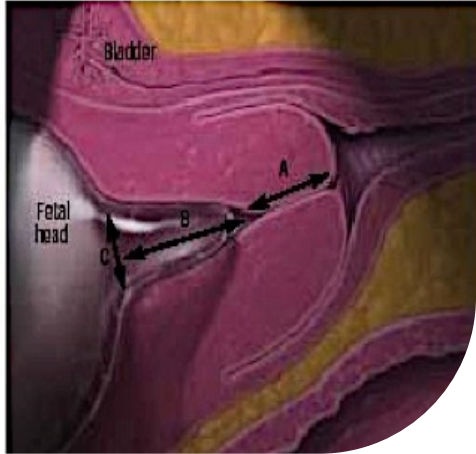
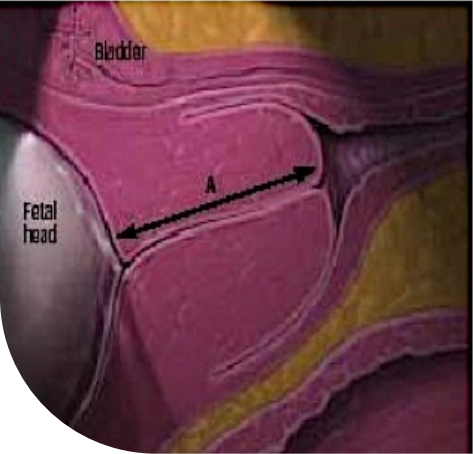
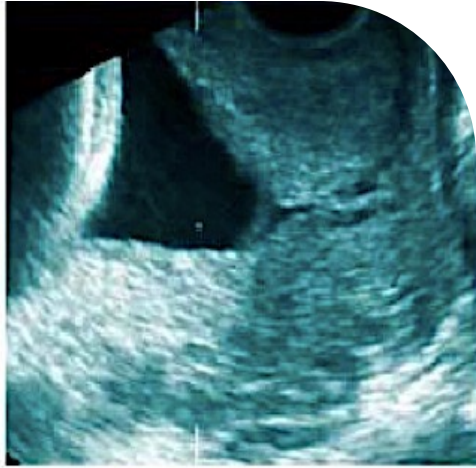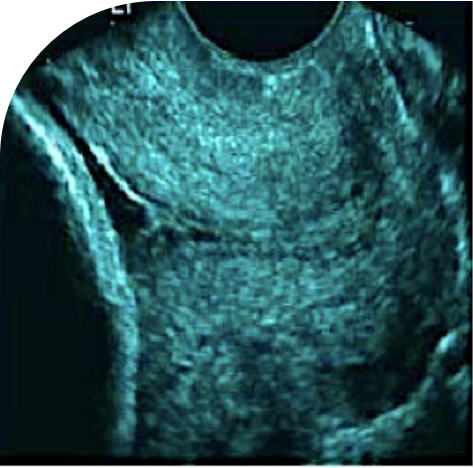


Normal Cervix (closed)

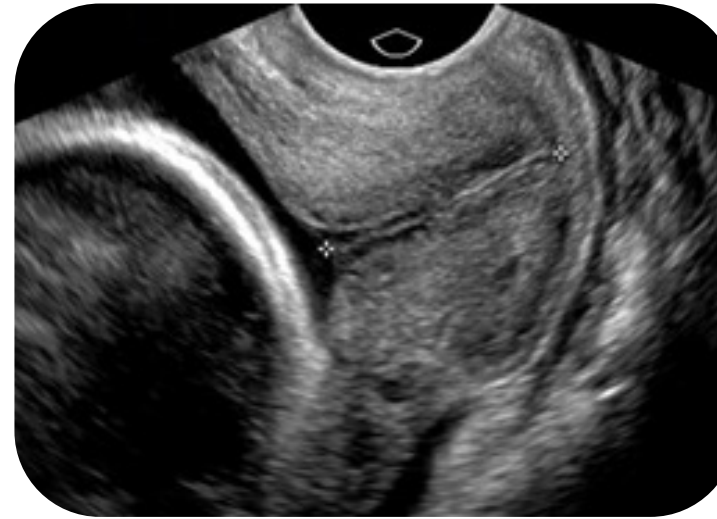
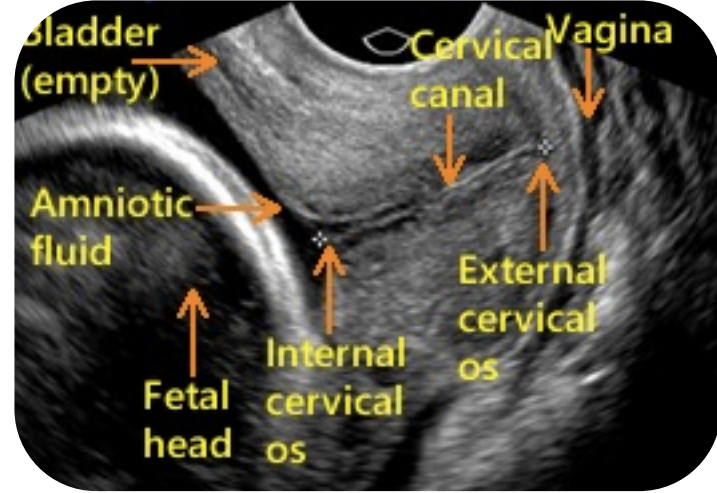
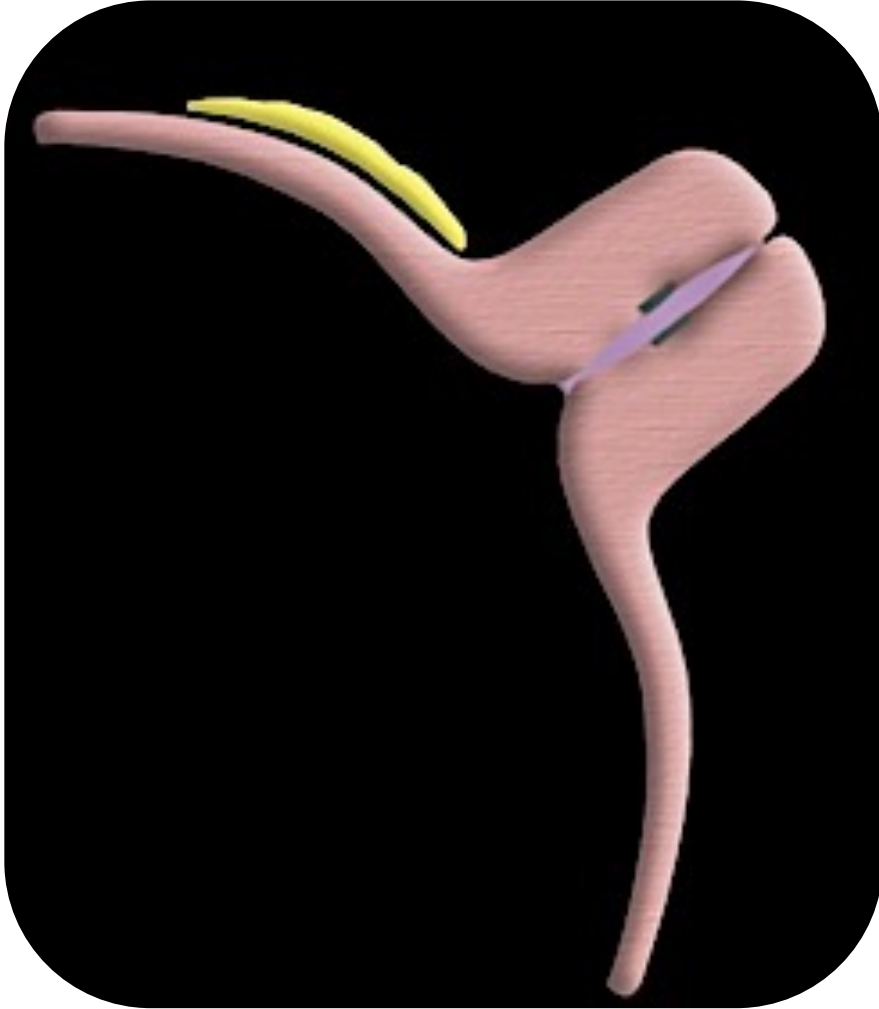


Incompetent Cervix (open)

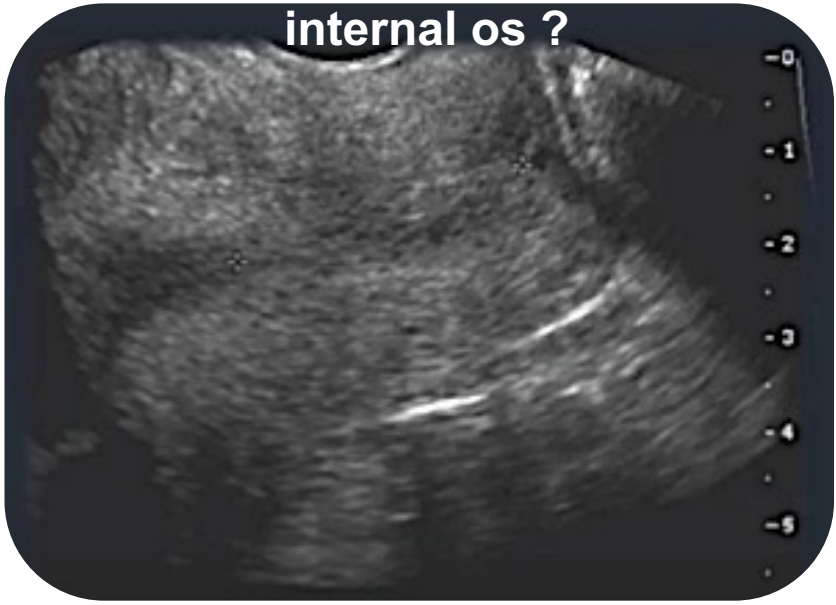
Serviksi Nasıl Ölçmeliyiz ?



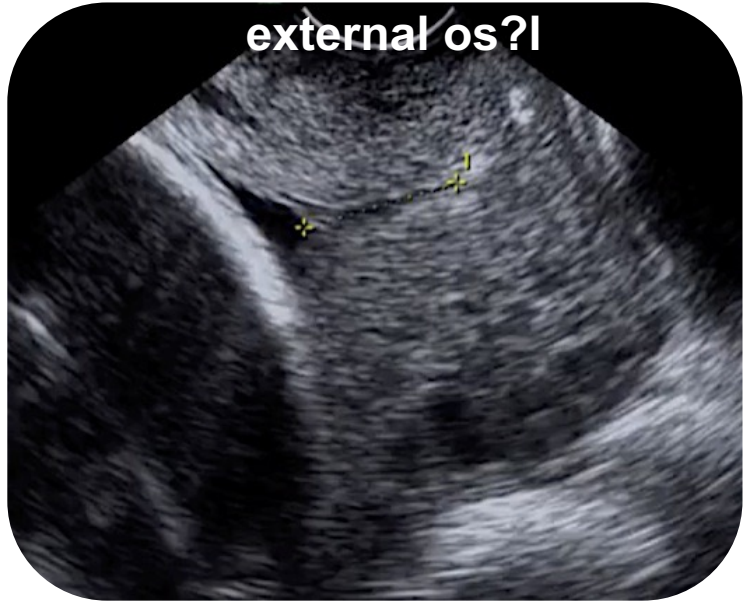
- ∞ TVUSG
- ∞ Görüntünün % 75'i serviks olmalı
- ∞ Anterior forniks = posterior forniks
- ∞ Mesane boş olmalı
- ∞ Internal os gözlenmeli
- ∞ Eksternal os gözlenmeli
- ∞ Servikal kanalın tamamı görülmeli
- ∞ Zaman ayırılmalı



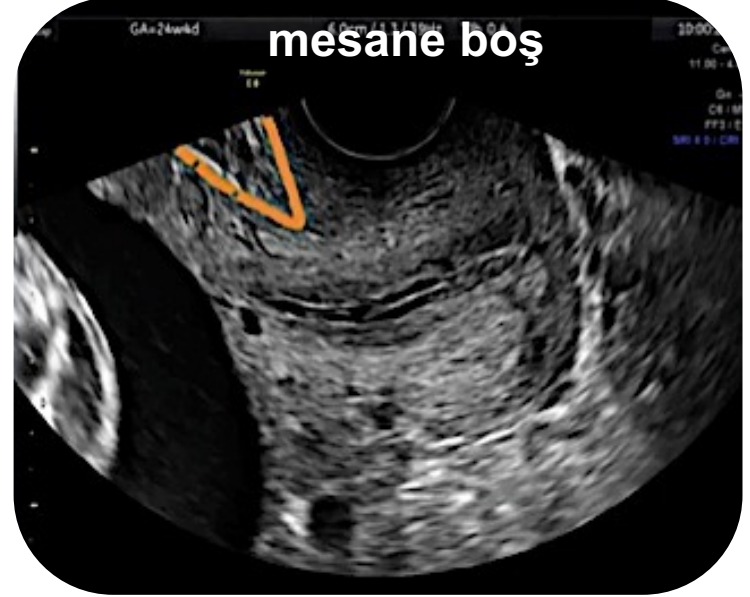
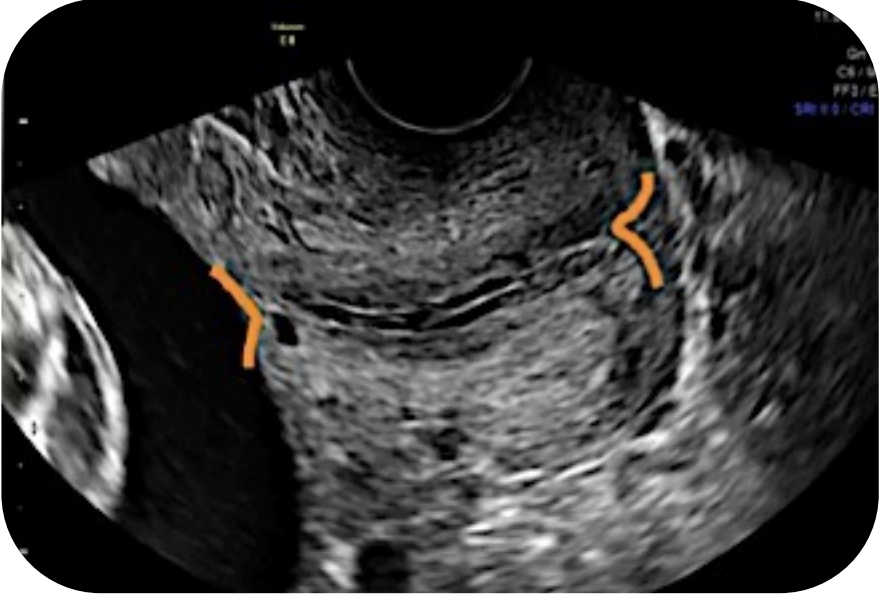
internal os ?



external os?!

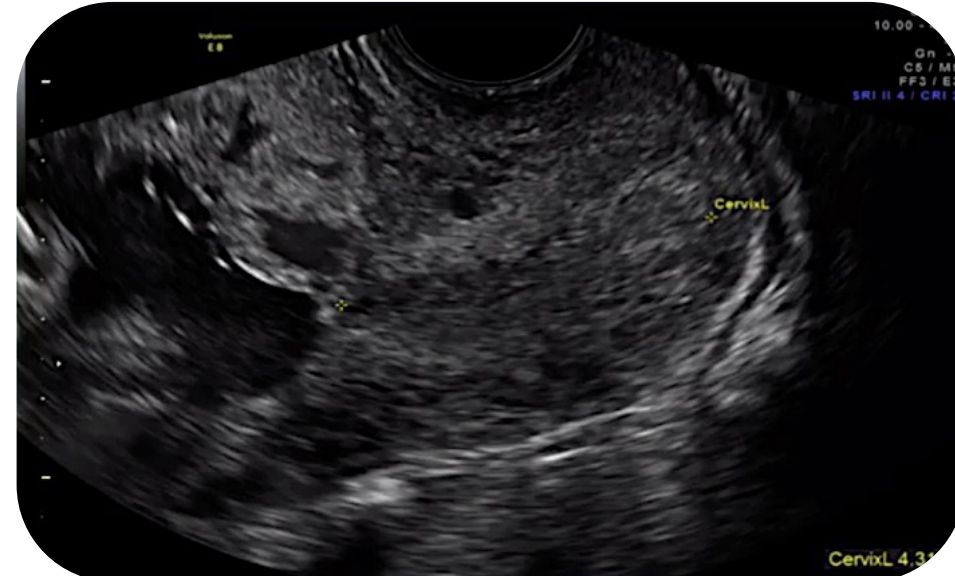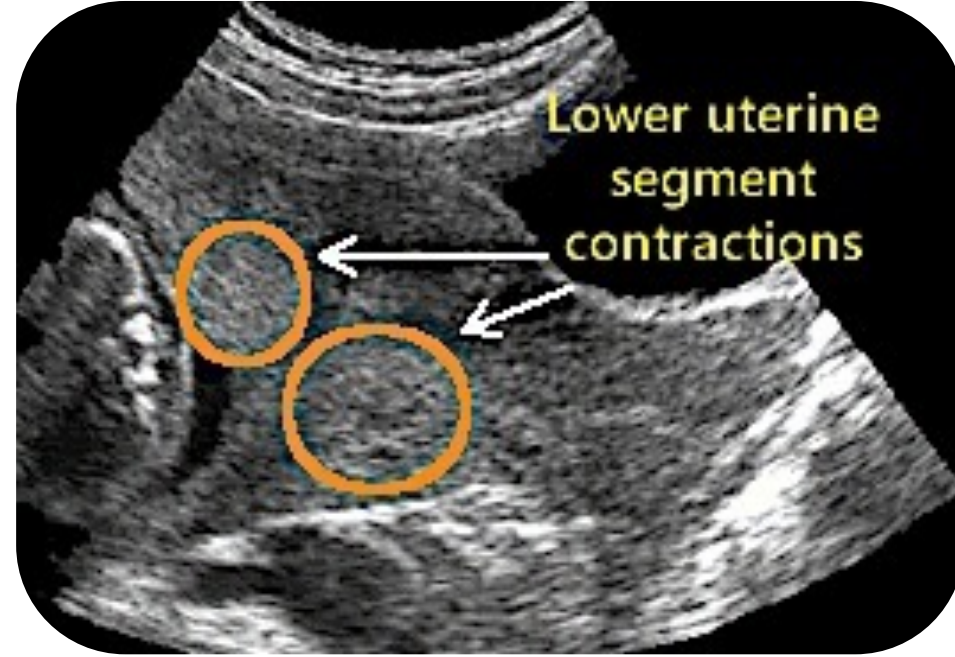


mesane boş

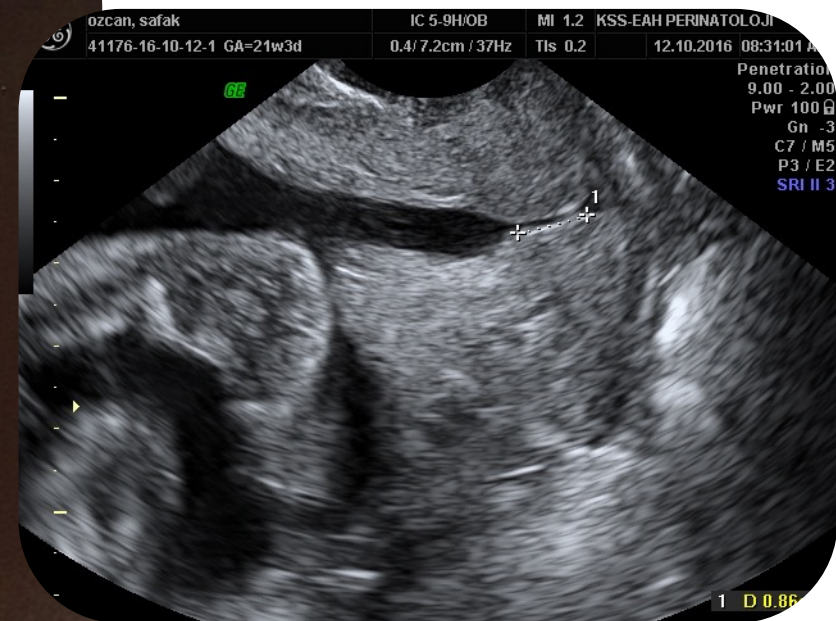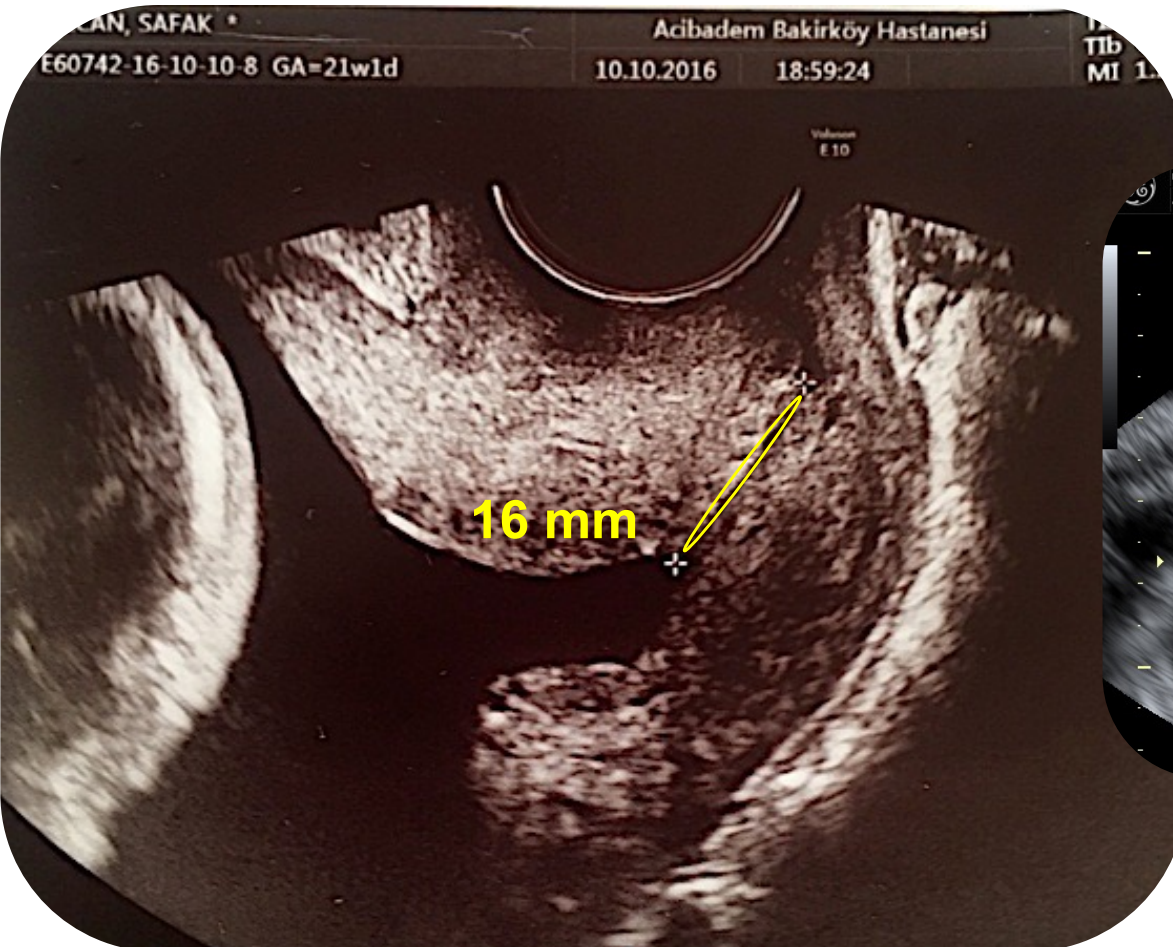


Alt uterin segment & kontraksiyon

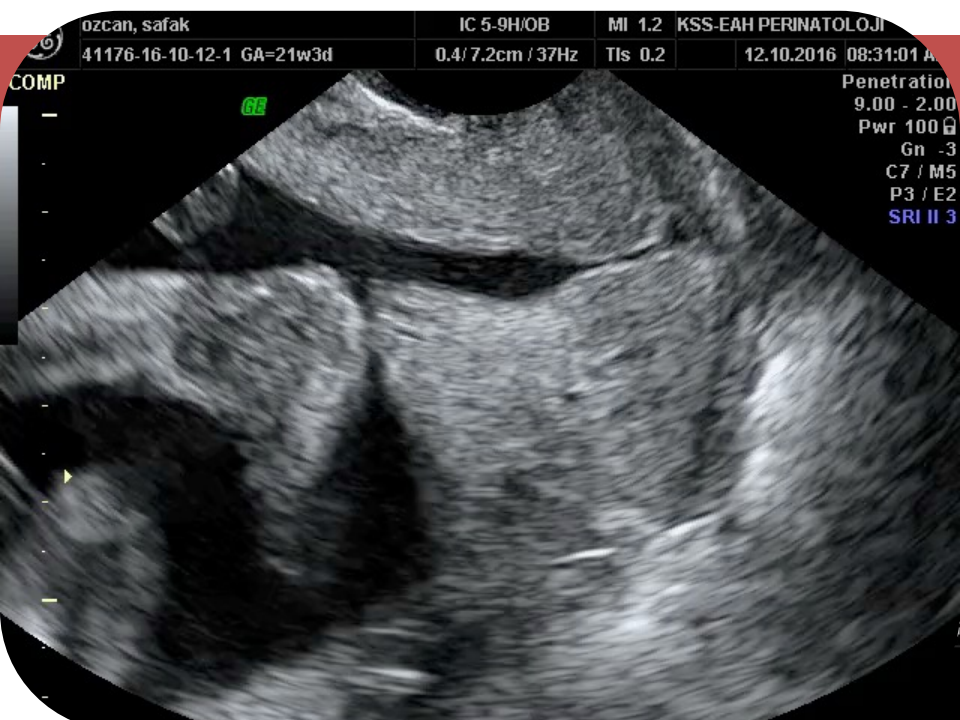- Endoservikal kanala bak
- Zaman harca
- Fetal başı it
- İnternal osu görmüyorsan kontraksiyon olarak düşün



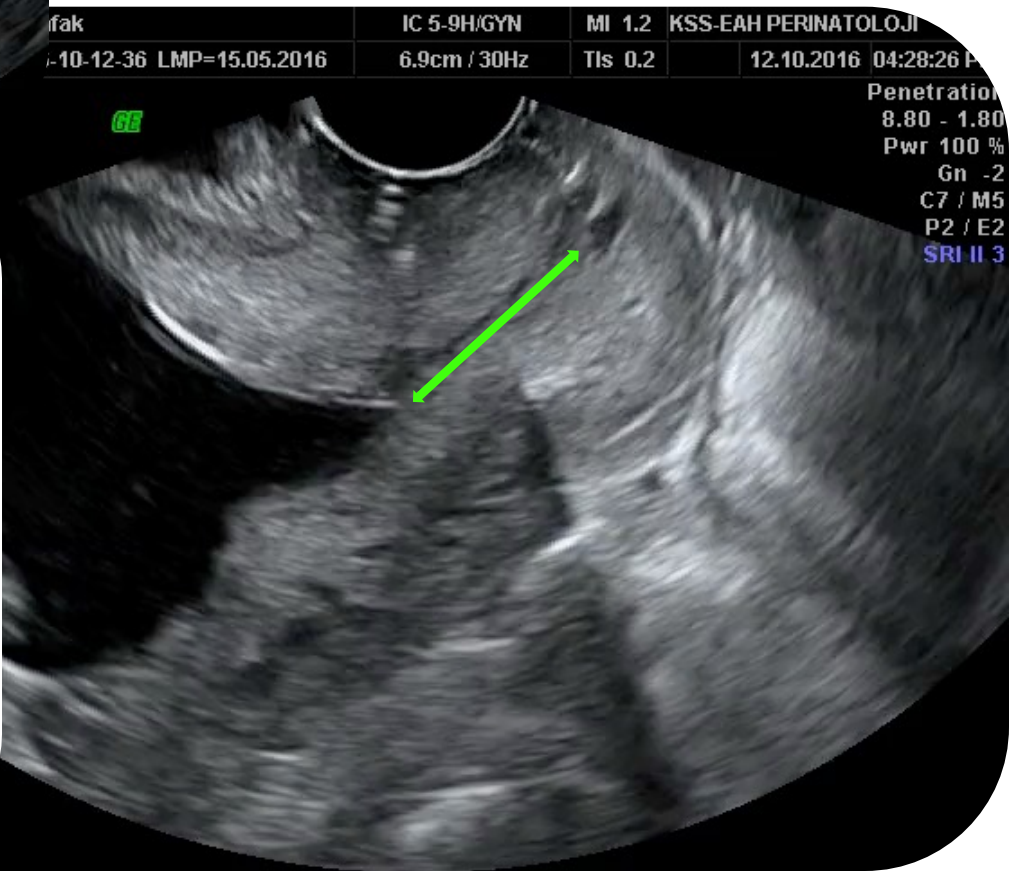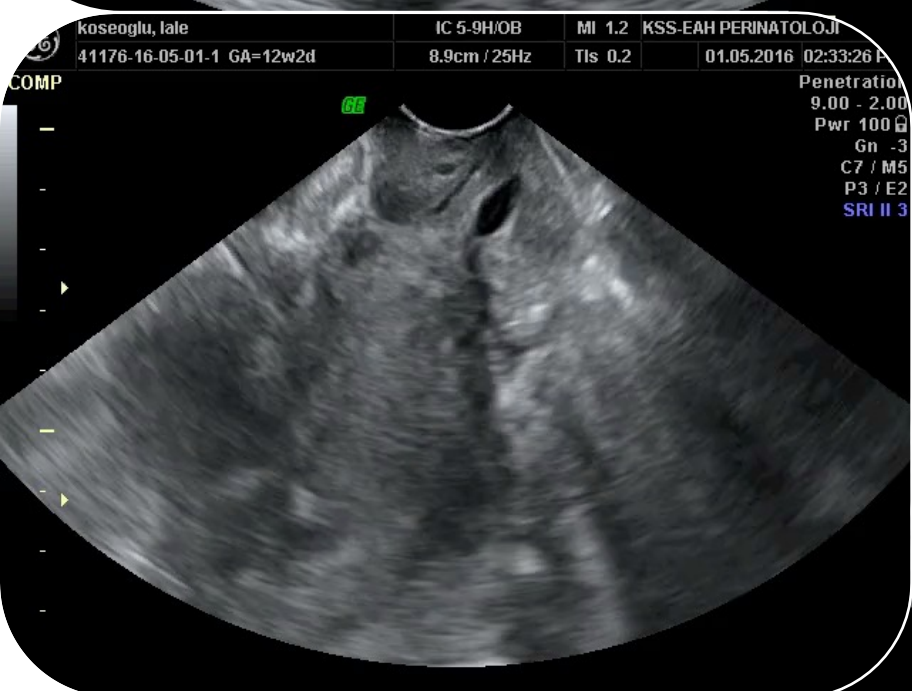ÖŞ, 32 y, G2P1, 21 weeks,

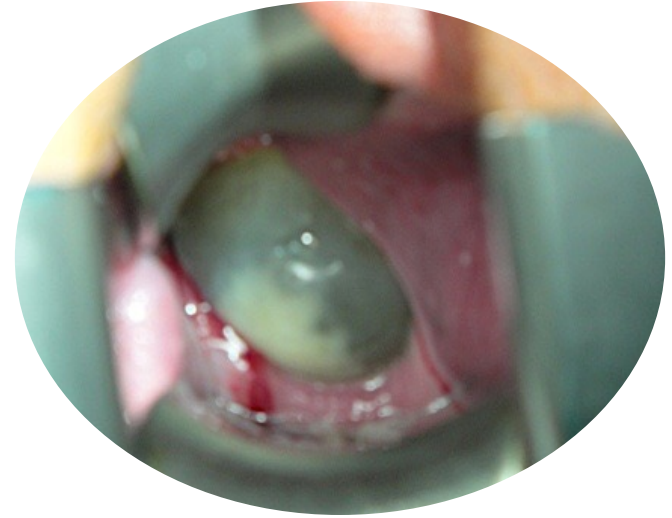
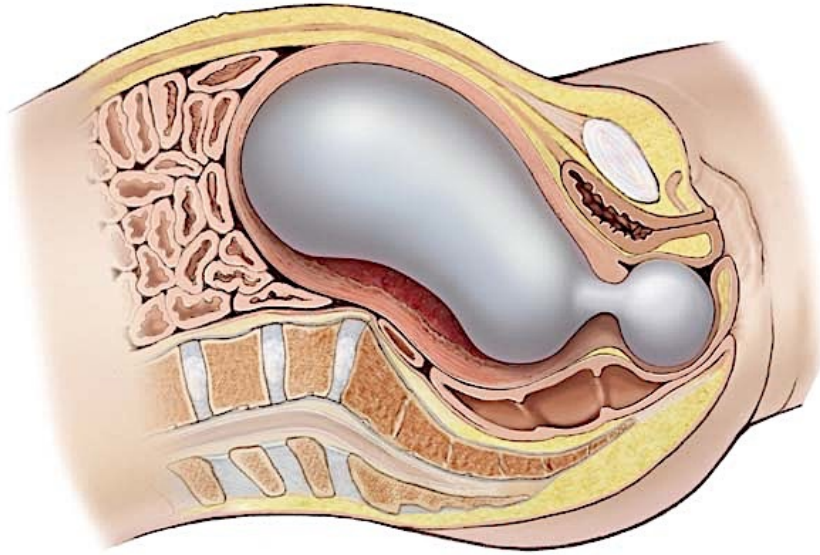


The day after



preop-postop usg





ACİL



Rescue
serklaj



Muyeneye
Dayalı

Serklaj

Kime? Ne Zaman?

Öykü

2. trimester kaybı
ve/veya preterm
doğum <34 hft

**12-14 hft -
Serklaj**

Ultrason

Preterm doğum
öyküsü
+
Serviks Uzunluğu
<25 mm

**16-23 hft -
Serklaj**

Muayene

Muayenede dilate
serviks <24 hft

**16-23 weeks
cerclage**

Gebelikte Minimal İnvazif Serklaj

**L/S veya L/T Abdominal Seklaj (LAC)
transvajinal yaklaşıma göre daha
invazifdir.**

- Daha önce başarısız vajinal serklaj
- Serviksin aşırı kısalmasına,skartrize olmasına veya yok olmasına yol açan durumlar. (Rekürren LEEP, laser konizasyon, trakelektomi)

Vajinal Serclaj / LAC

Multicenter randomize kontrollu çalışma: Alt vajinal, yüksek vajinal ve LAC

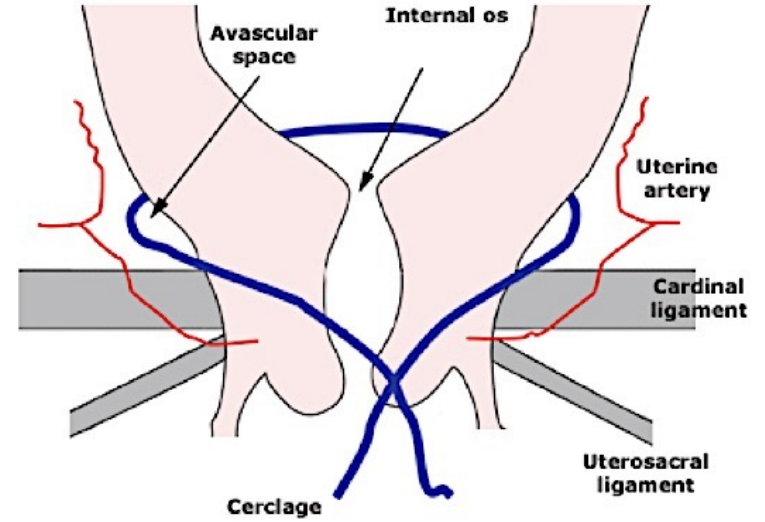
- 111/139' daha önce başarısız vajinal serklaj 33;39;39
- <32 gebelik haftasından önce doğum

	Preterm Doğum < 32 hft RR 0.23; 95% CII, 0.07-0.76; P=.0157).	Fetal Kayıp RR, 0.12; 95% CI 0.016-0.93; P=.02).
Transabdominal serklaj	3/33 %8	1/39
Alt Transvaginal serklaj	11/33 %33	3/ 39
Üst Transvaginal serklaj	15/39 %38	

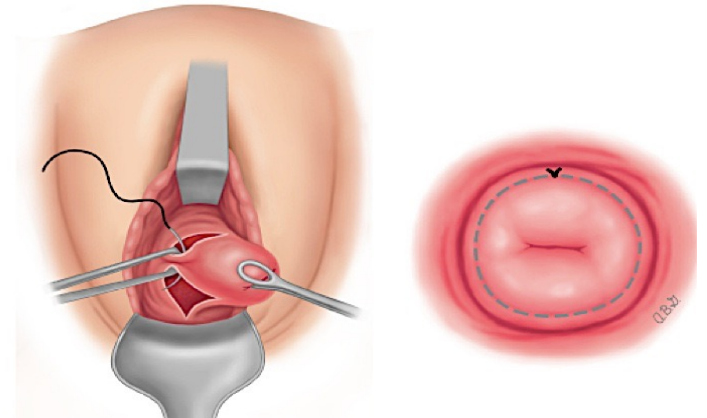
Transabdominal Yaklaşım Neden Daha Etkili

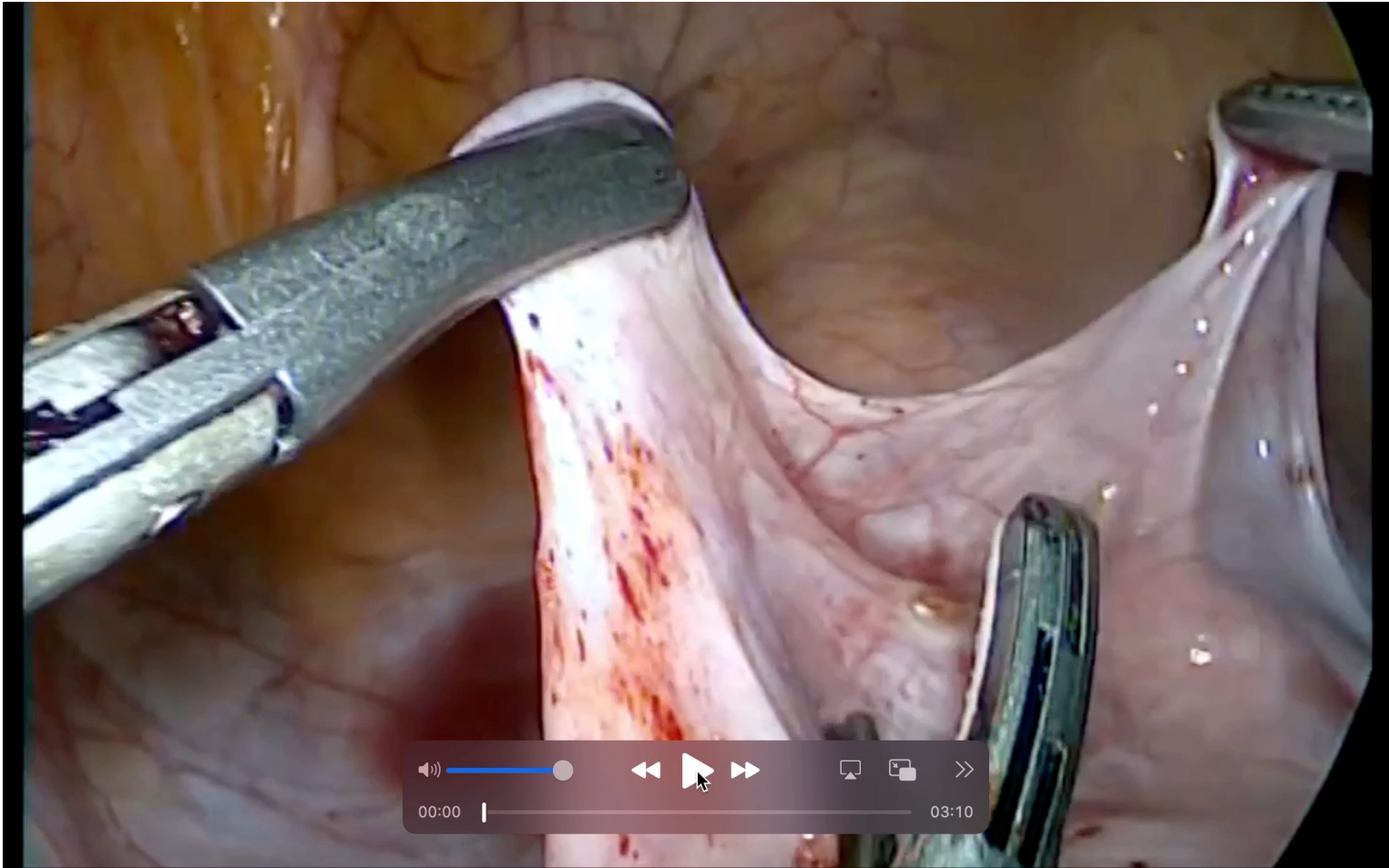
- ∞ İnternal os daha yakın yerleşim
- ∞ Uterus büyürken kaudal sütün migrasyon riskinin düşük olması
- ∞ Vajinadaki yabancı cisim reaksiyonunun daha az olması

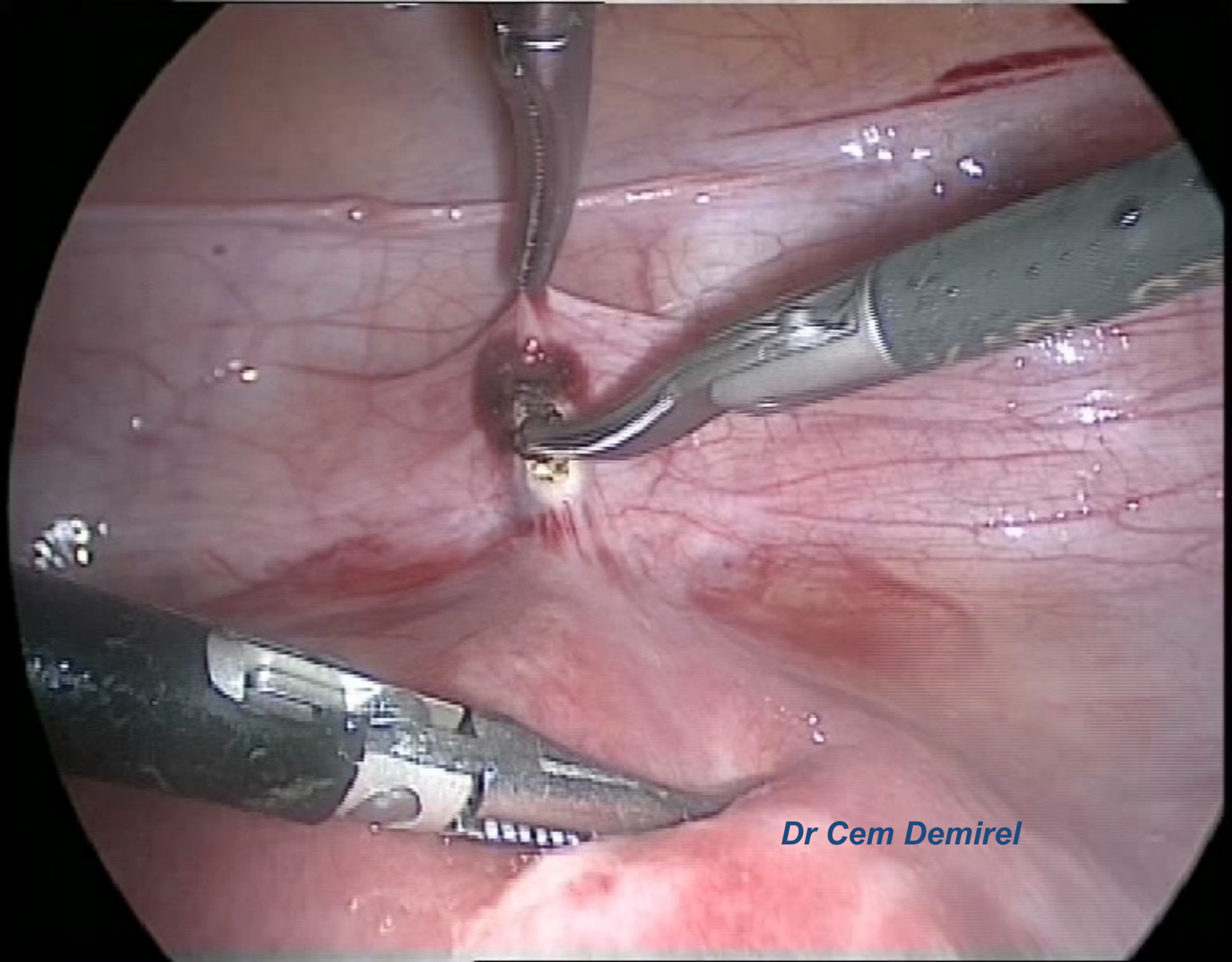
Transabdominal cerclage



Shirodkar cerclage





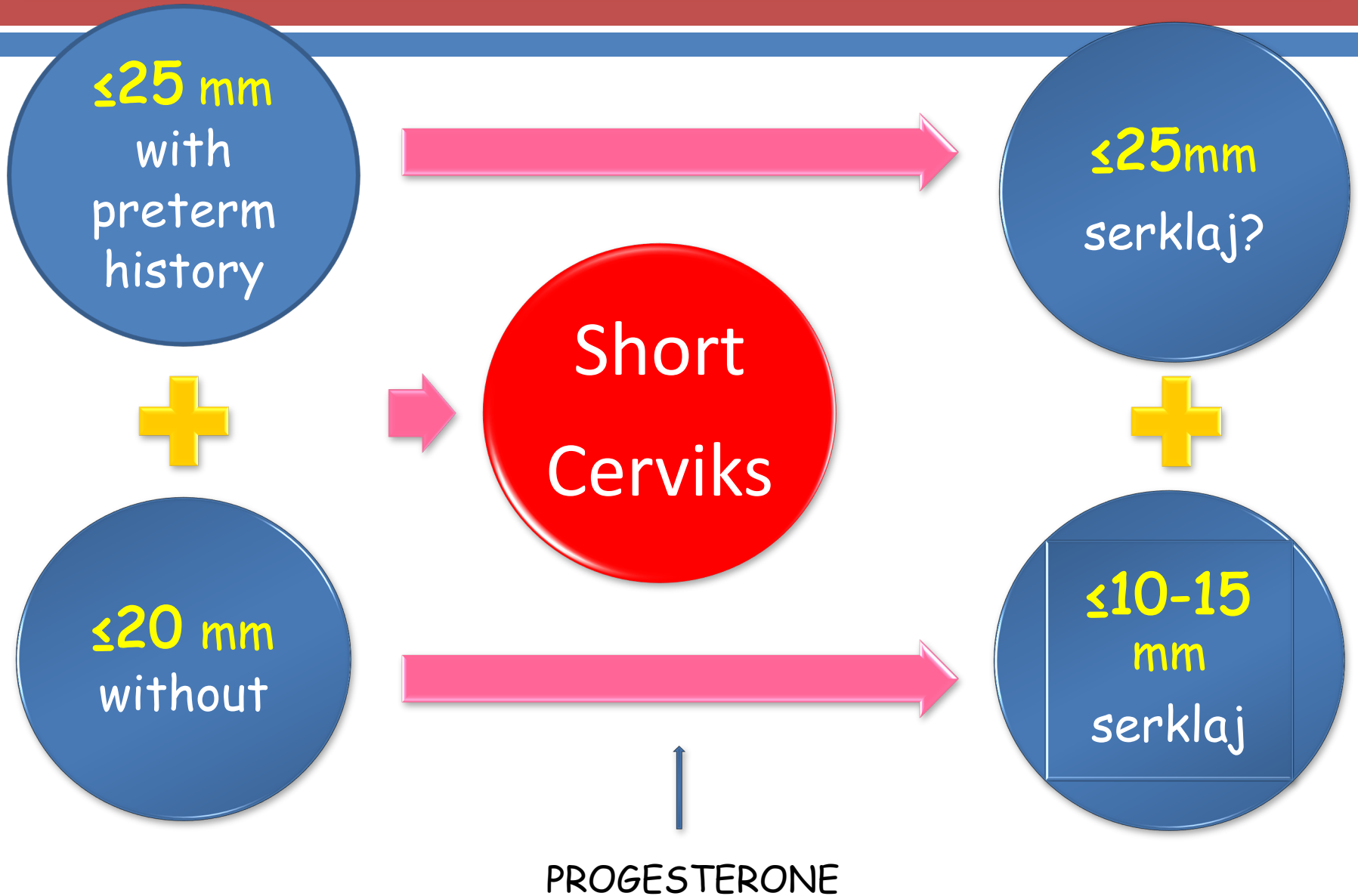


Dr Cem Demirel

Komplikasyonlar

- ∞ Kan kaybı
- ∞ Perioperatif enfeksiyonlar.
- ∞ L/T'e geçiş
- ∞ Thromboembolizm
- ∞ Uterine artere kompresyon
- ∞ FGR

Serklaj



Serklaj Yapılmamalı

☞ PPRM

☞ Aktif Kanama

☞ Koryoamnionitis

☞ Eylemde

☞ Düzenli kontraksiyonlar

☞ Kısa serviks + çoğul gebelik?

Serklaj

Endikasyonu iyi koymak gerekir
Zamanlama önemli
Eđitim-Deneyim

